

Blades & Bullets: MDCT Imaging of Penetrating Torso Injury

Eastern Radiological Society
Charleston, SC 2014

K.SHANMUGANATHAN MD

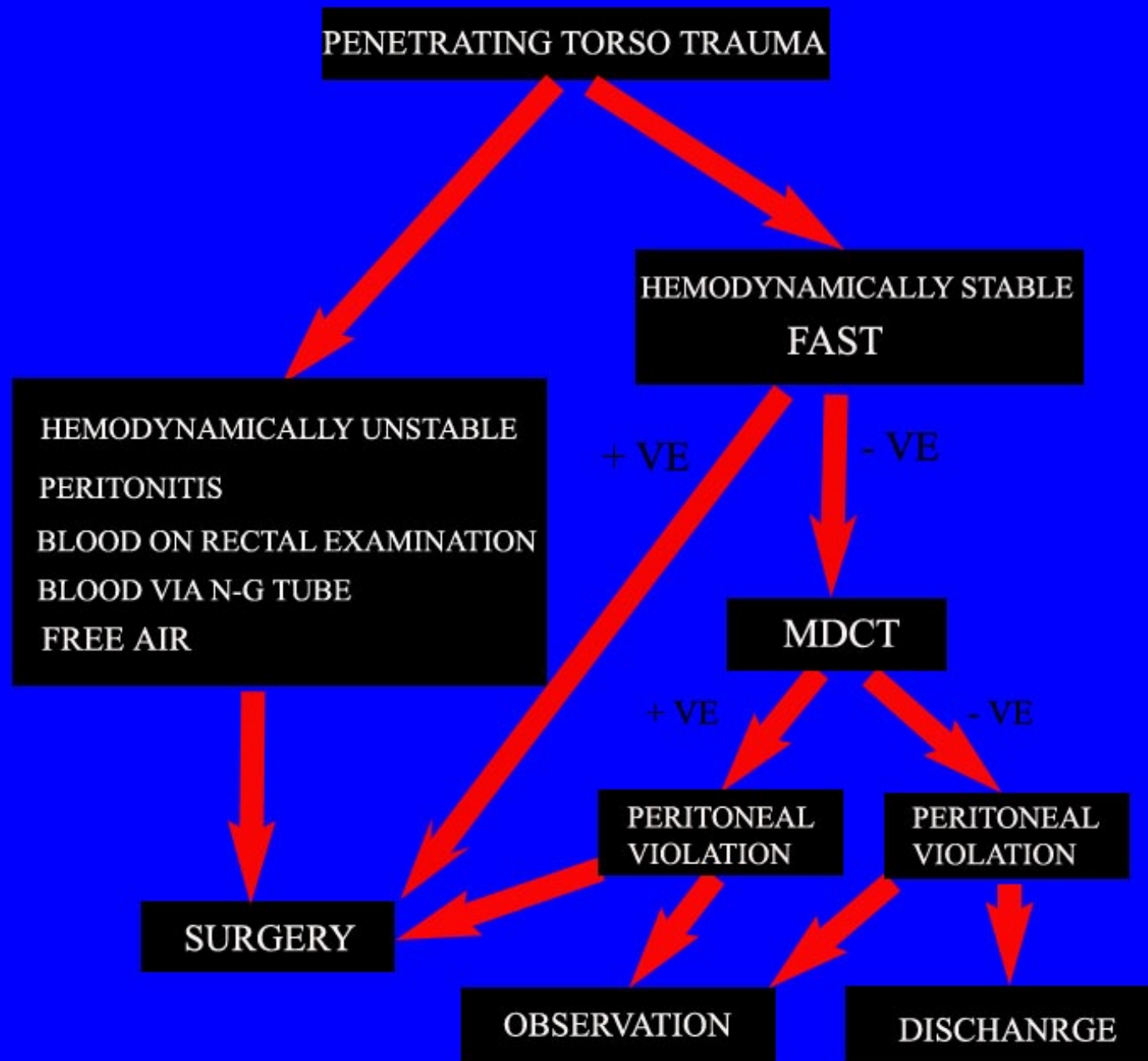


PENETRATING TORSO TRAUMA

OBJECTIVES

- Who & how - MDCT
- Peritoneal violation
- Multiple compartment injury
- Diagnosis of bowel & mesenteric injury

ALGORITHM TO TRIAGE PENETRATING TORSO TRAUMA PATIENTS



TRIPLE CONTRAST MDCT CT IN PENETRATING TORSO TRAUMA

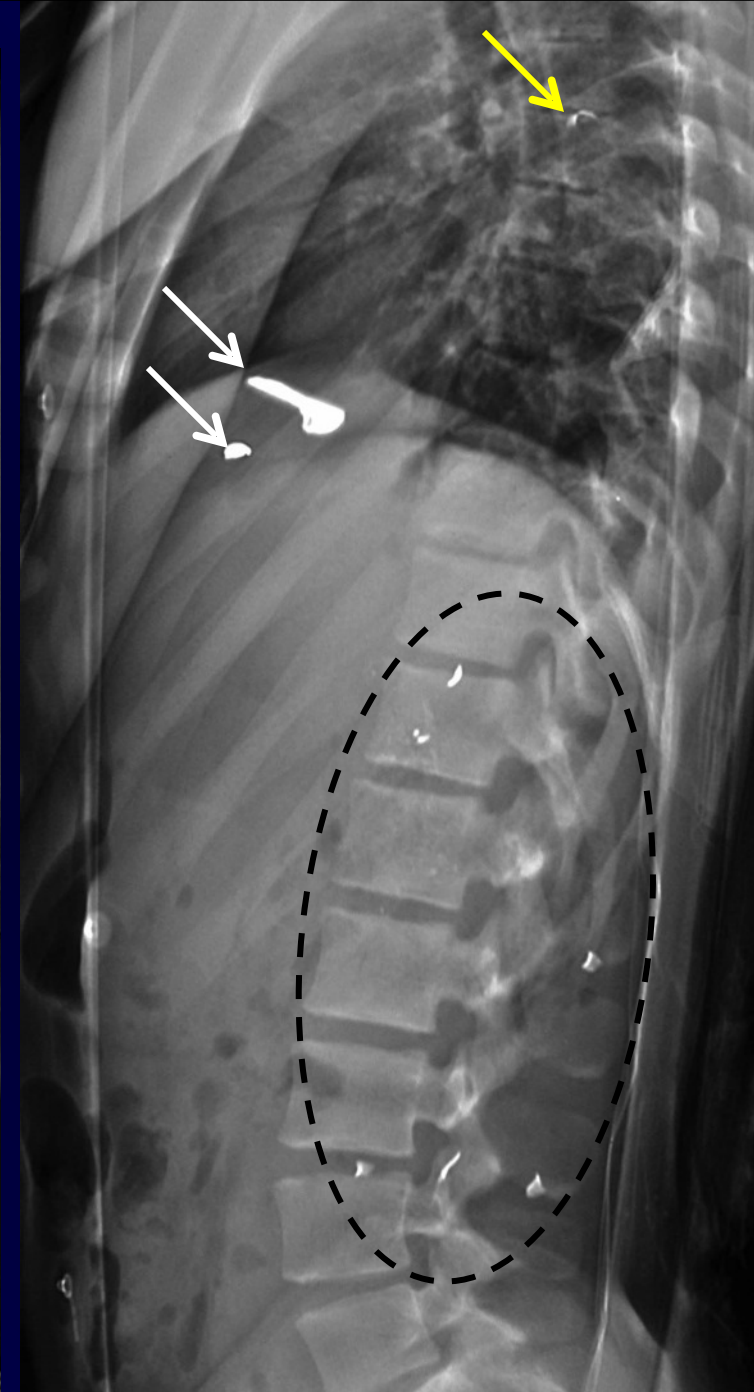
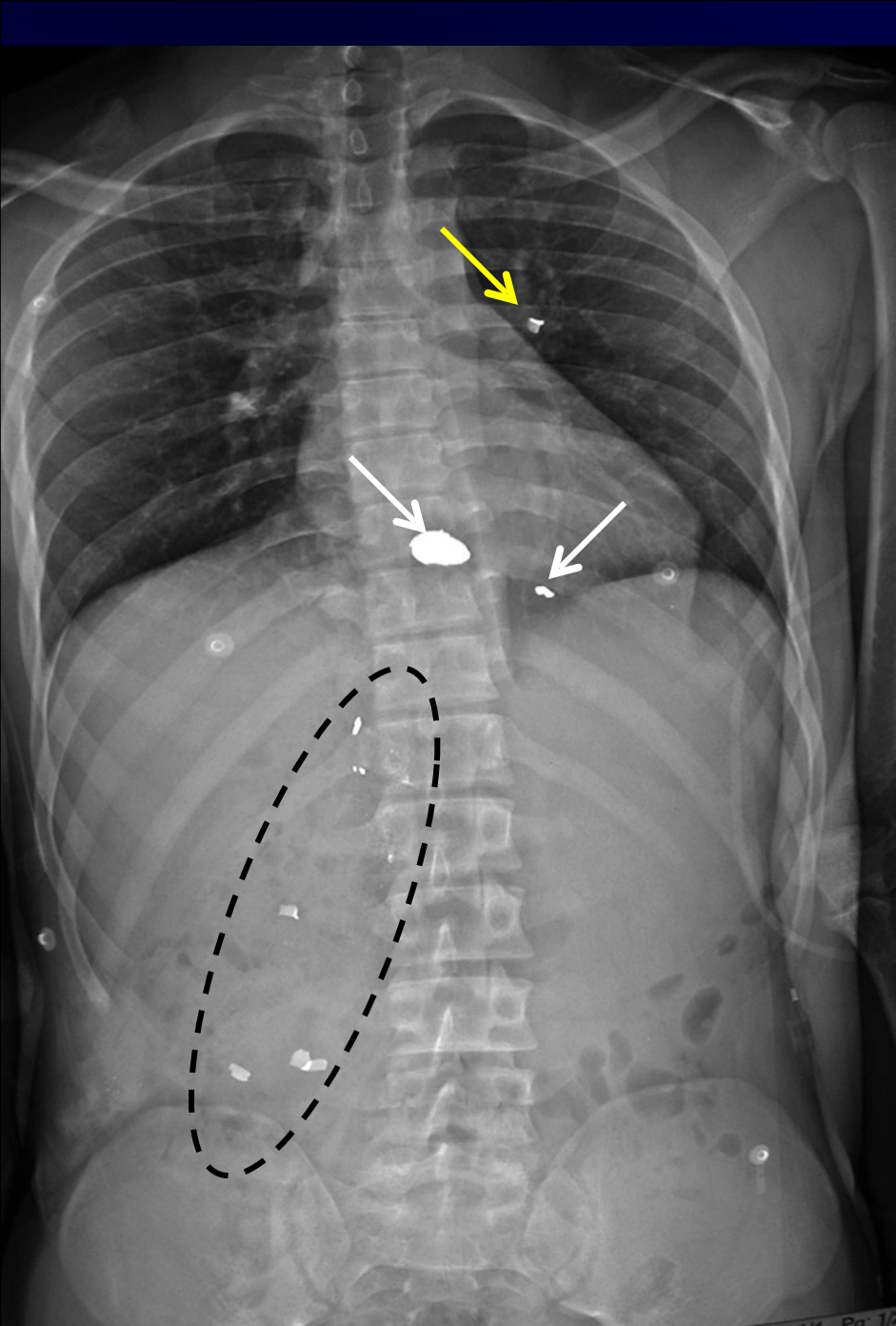
TECHNIQUE

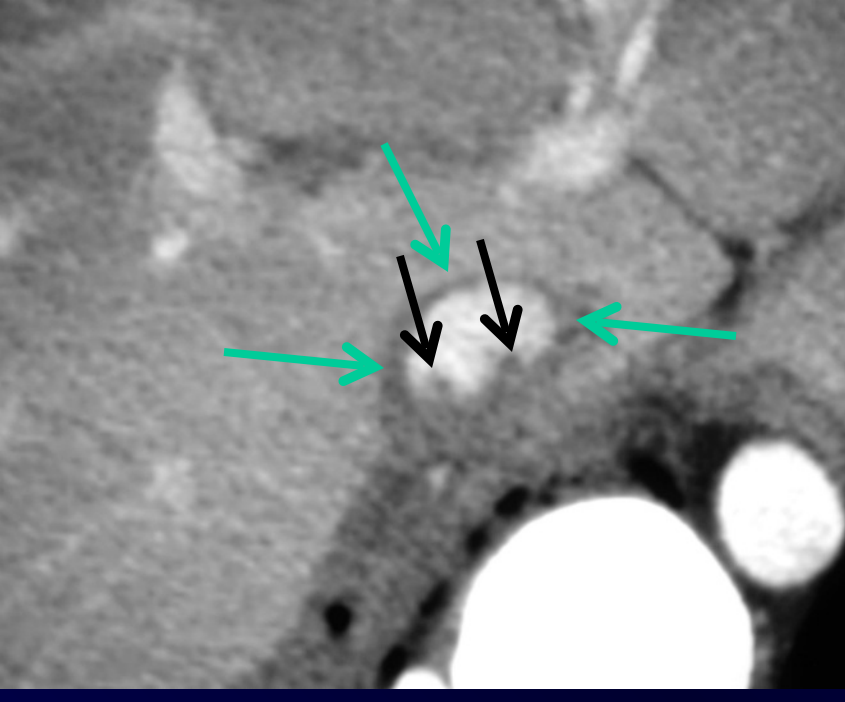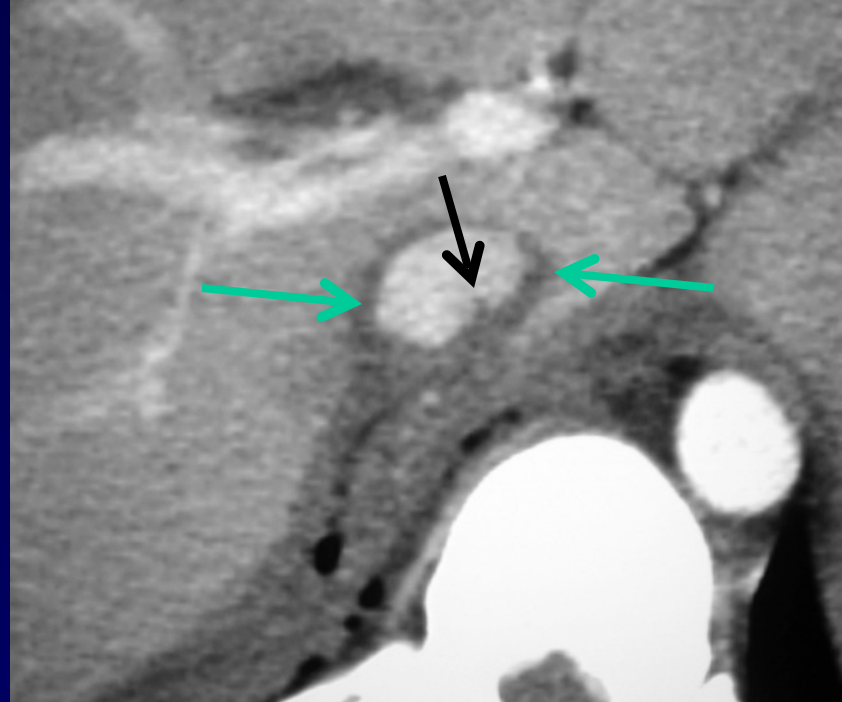
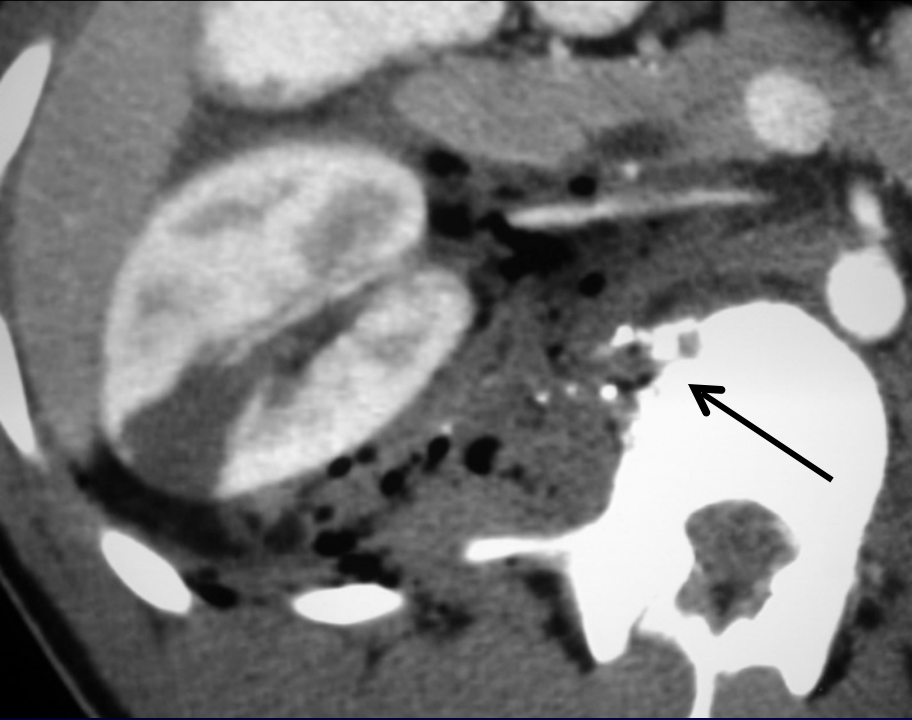
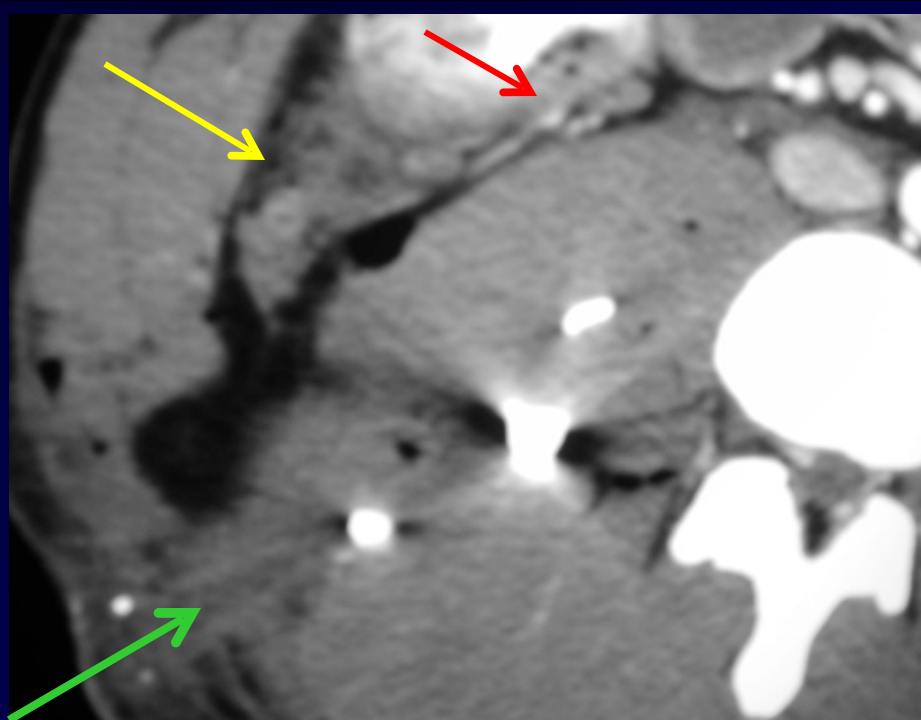
- Oral contrast material (500 - 600 mL)
- Rectal contrast material (1 - 1.5 L)
- IV contrast material - 100 ml 350 mg I₂/ml

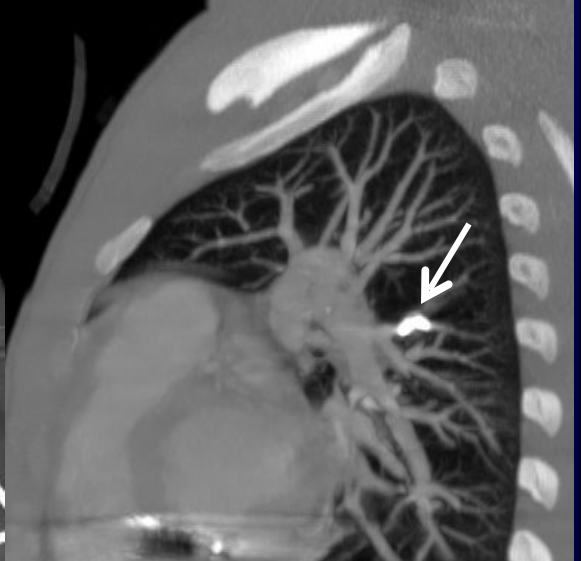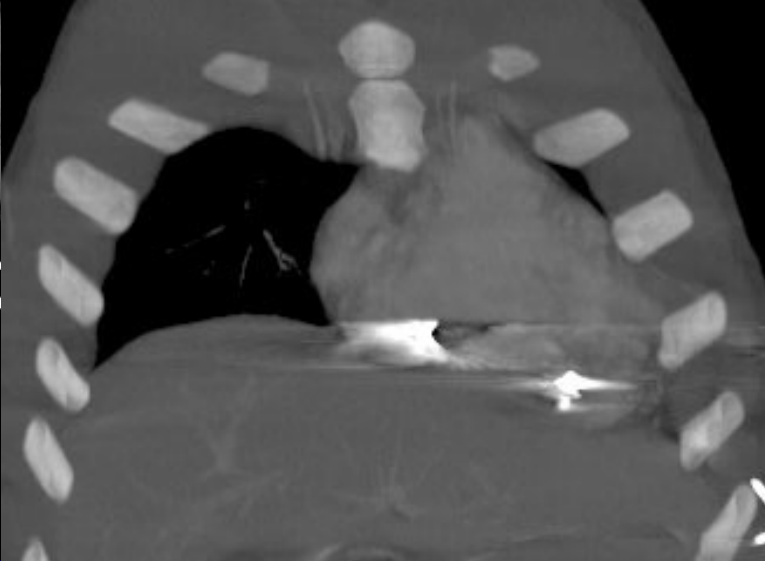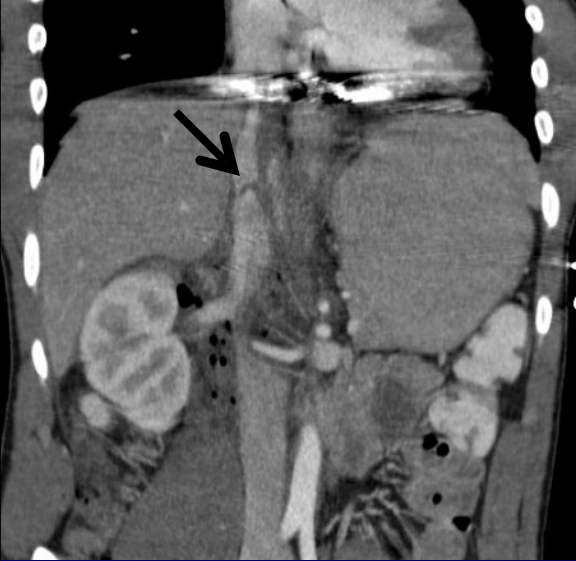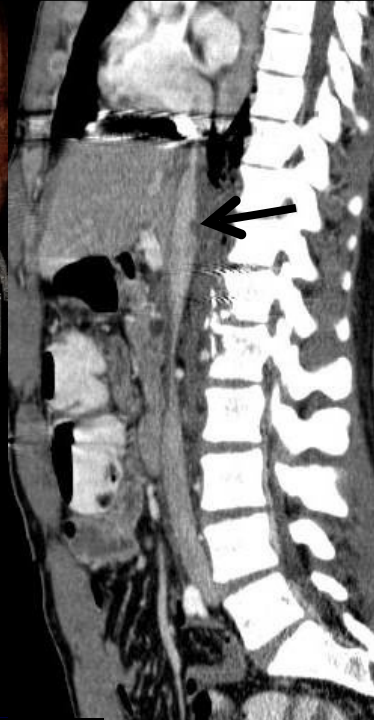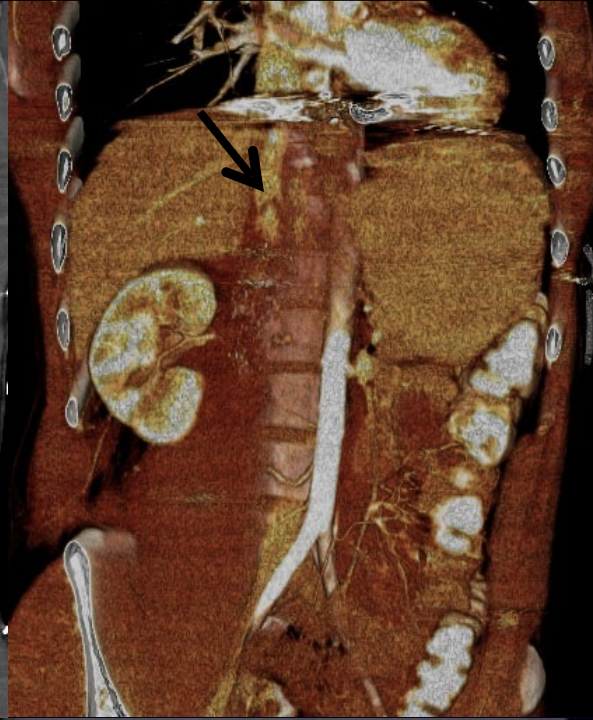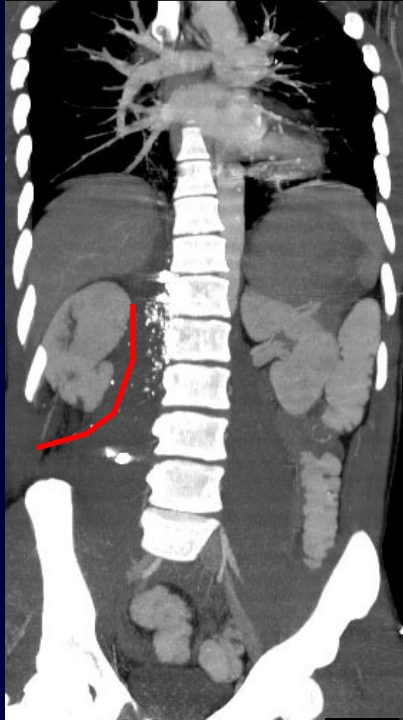
TRIPLE CONTRAST SPIRAL CT IN PENETRATING TORSO TRAUMA

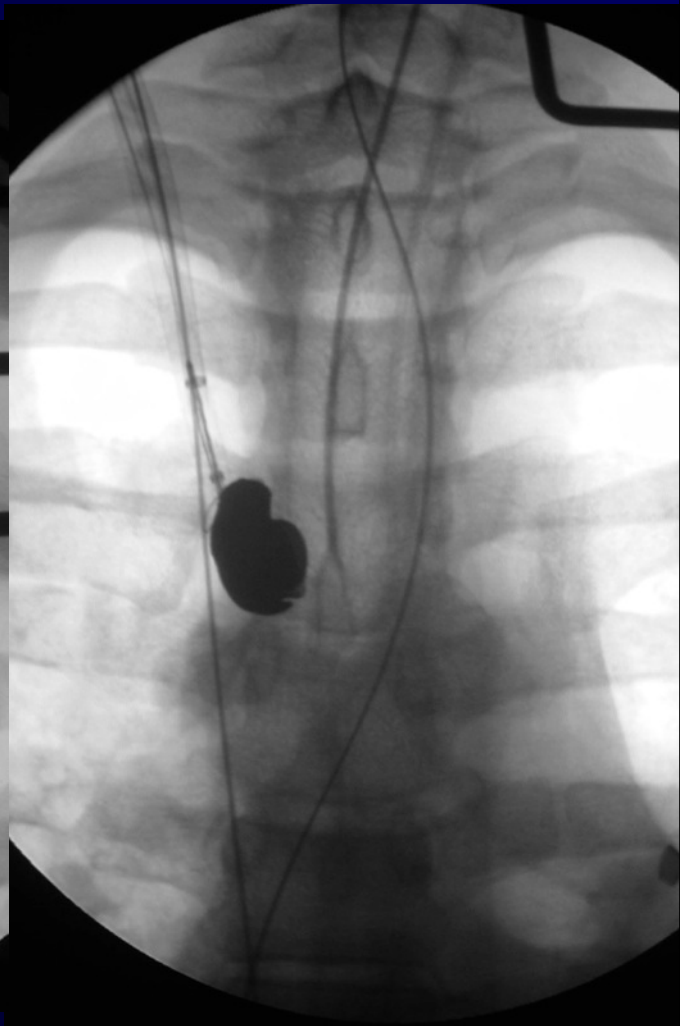
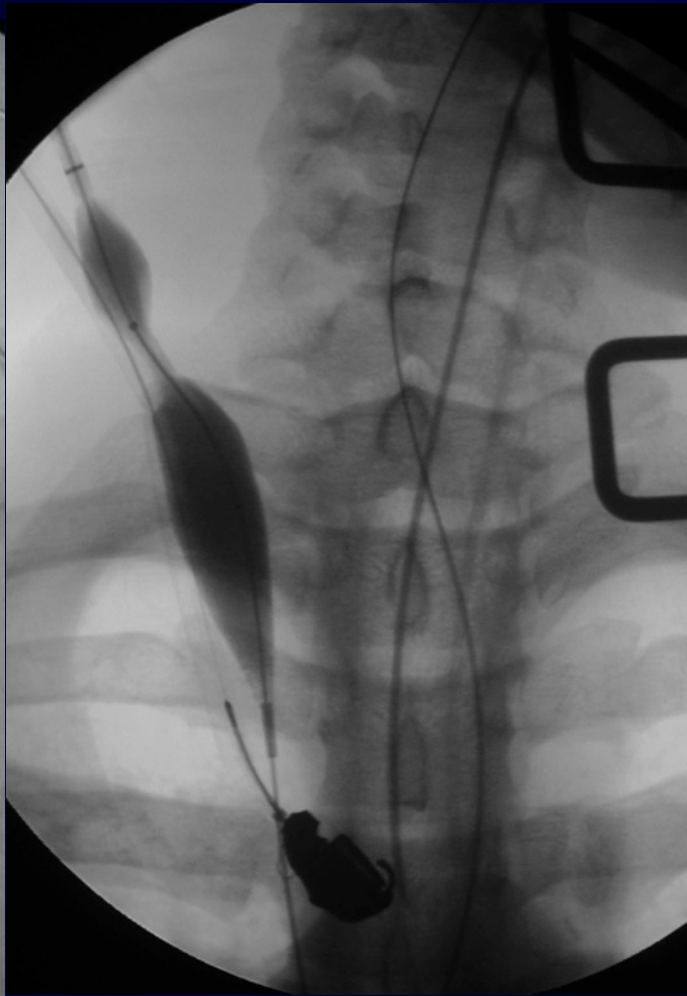
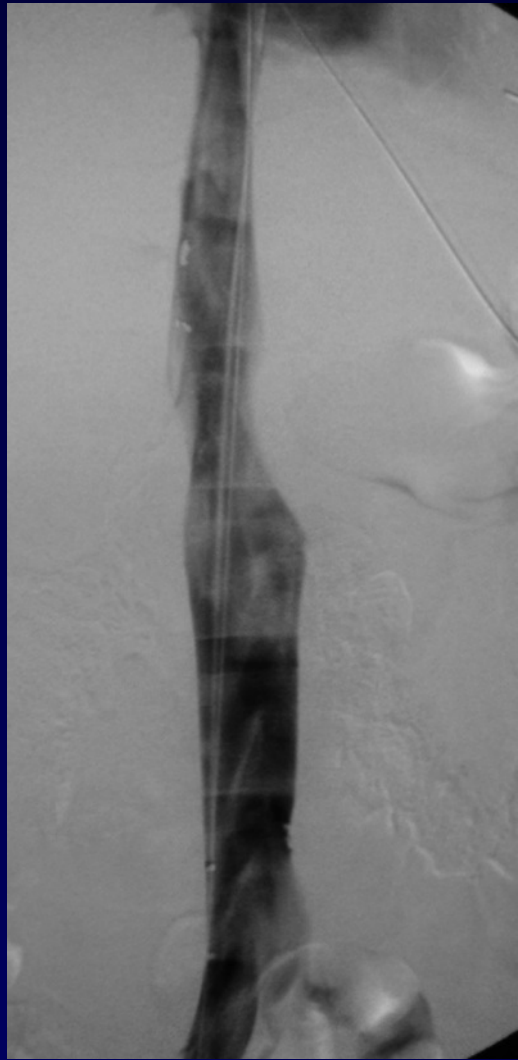
PERITONEAL VIOLATION = + CT

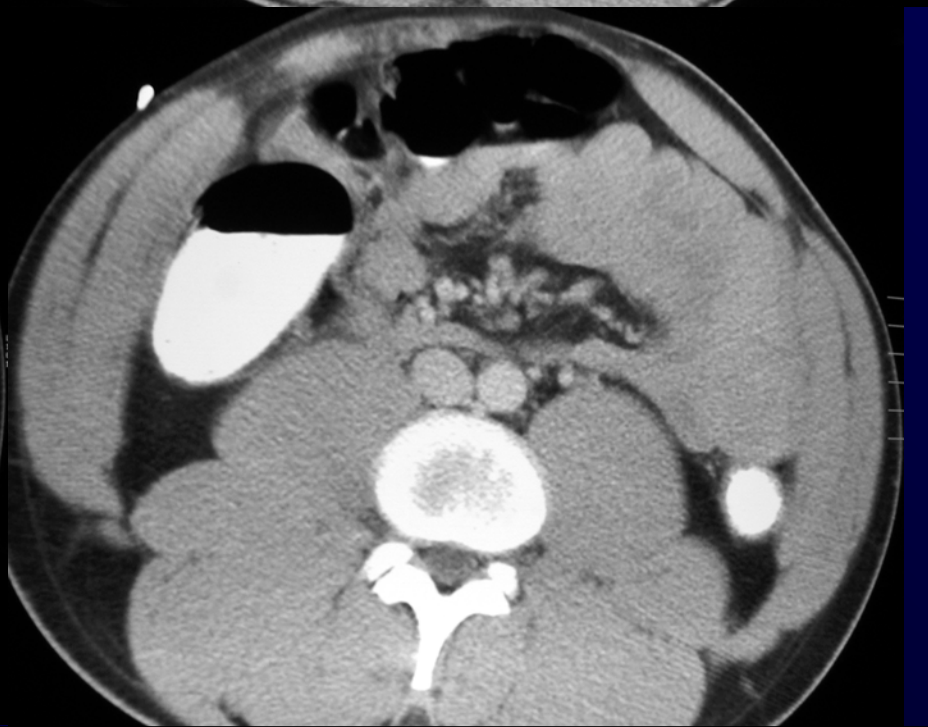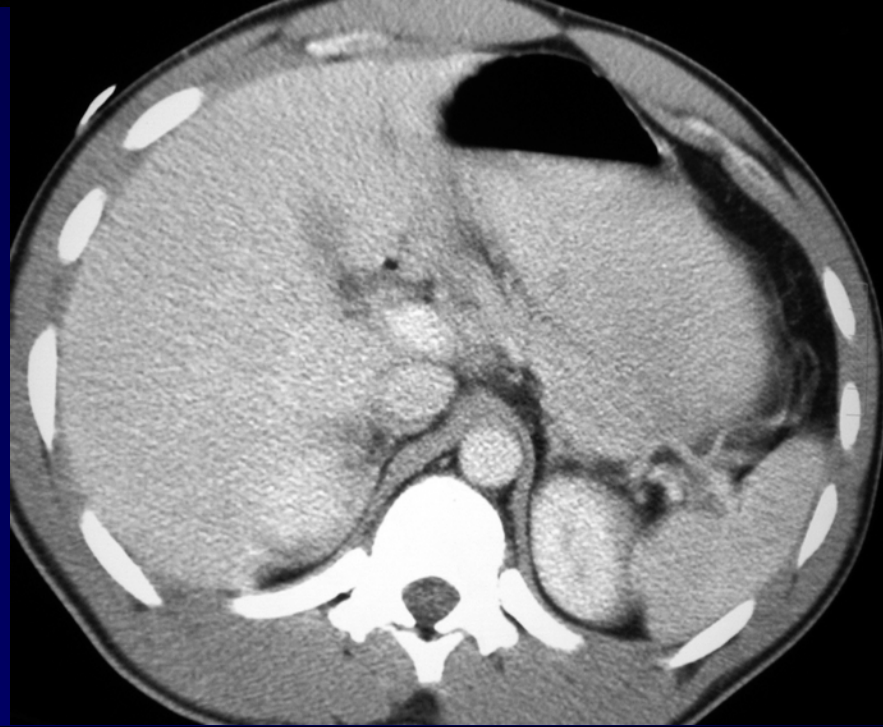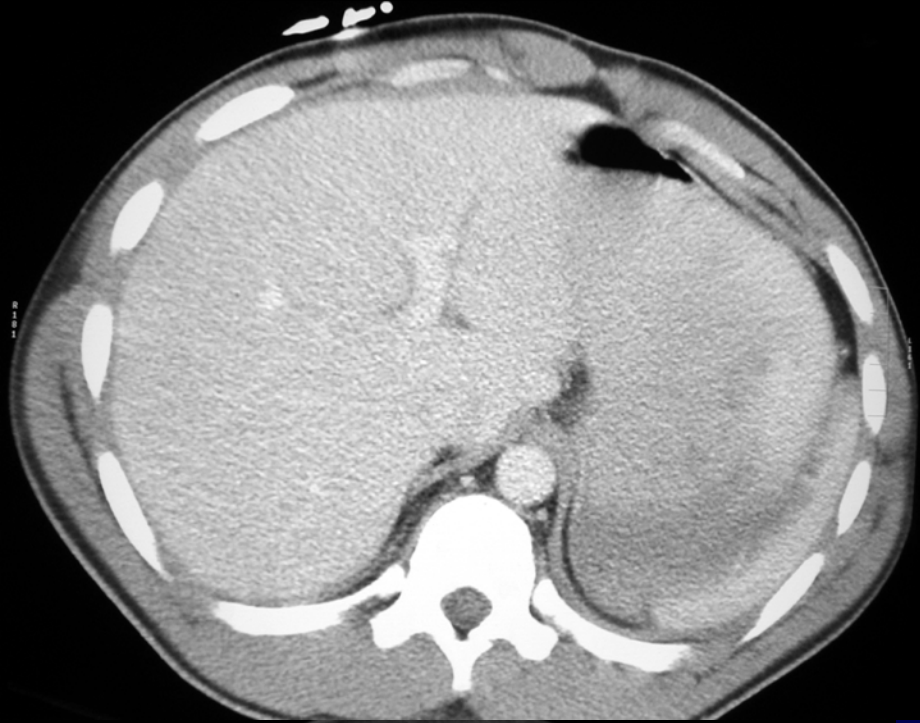
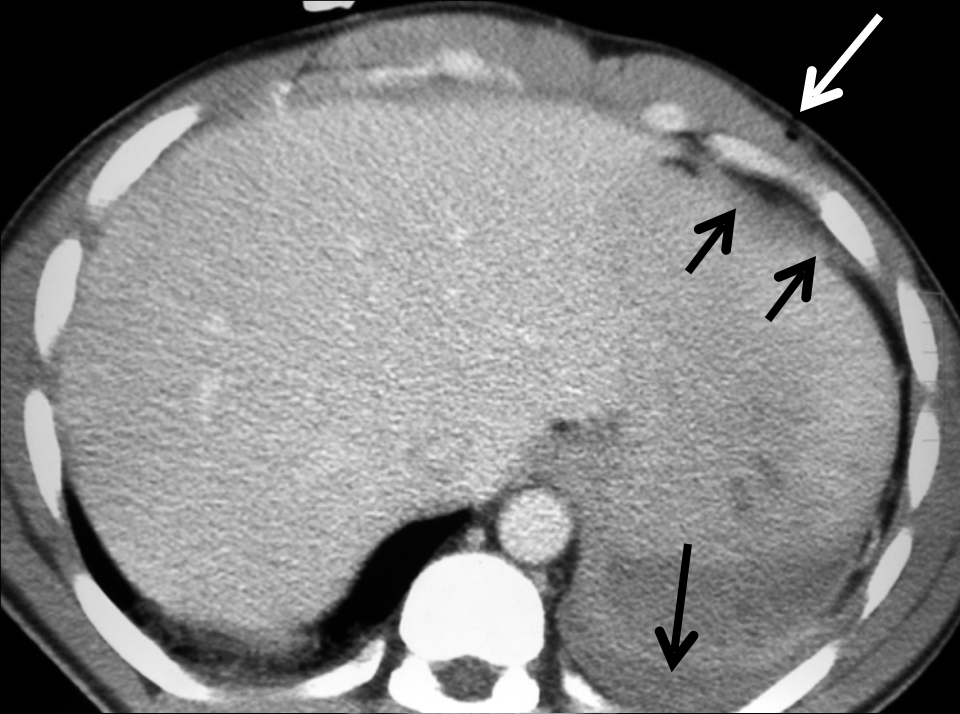- Free intraperitoneal air
- Free intraperitoneal fluid
- Intraperitoneal organ injury
- Bullet or stab WT – peritoneal extension

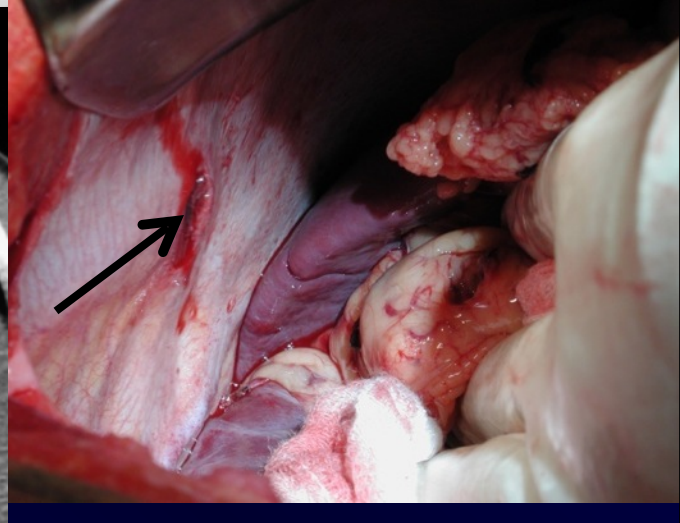
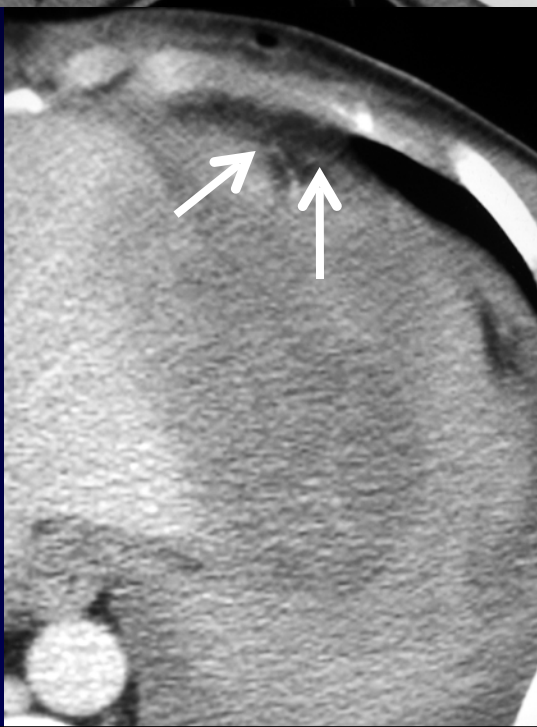
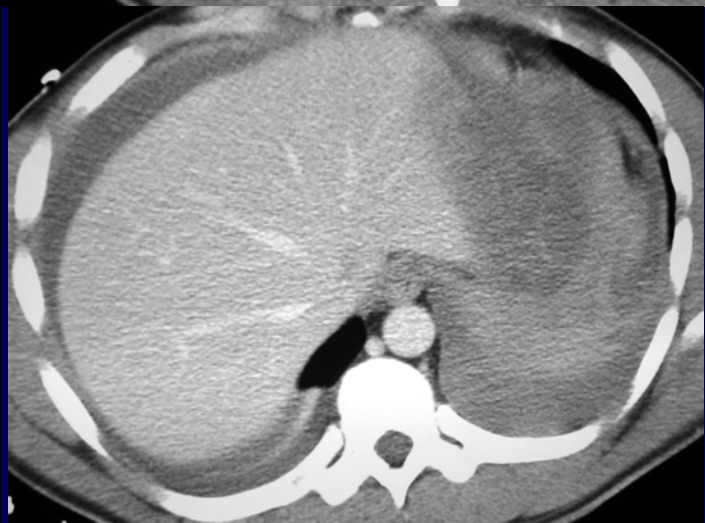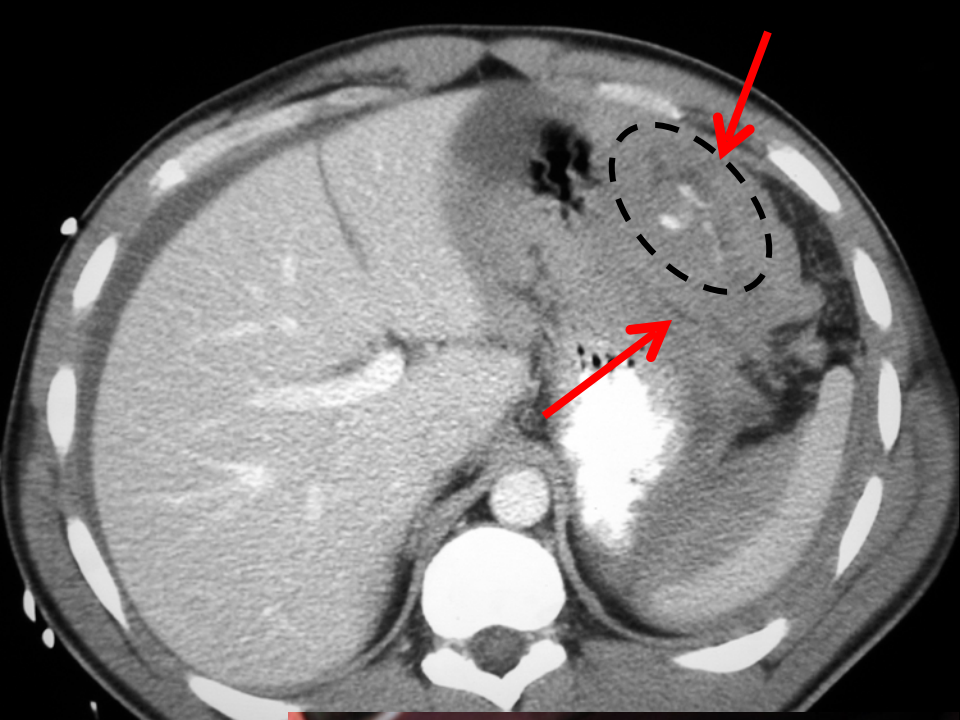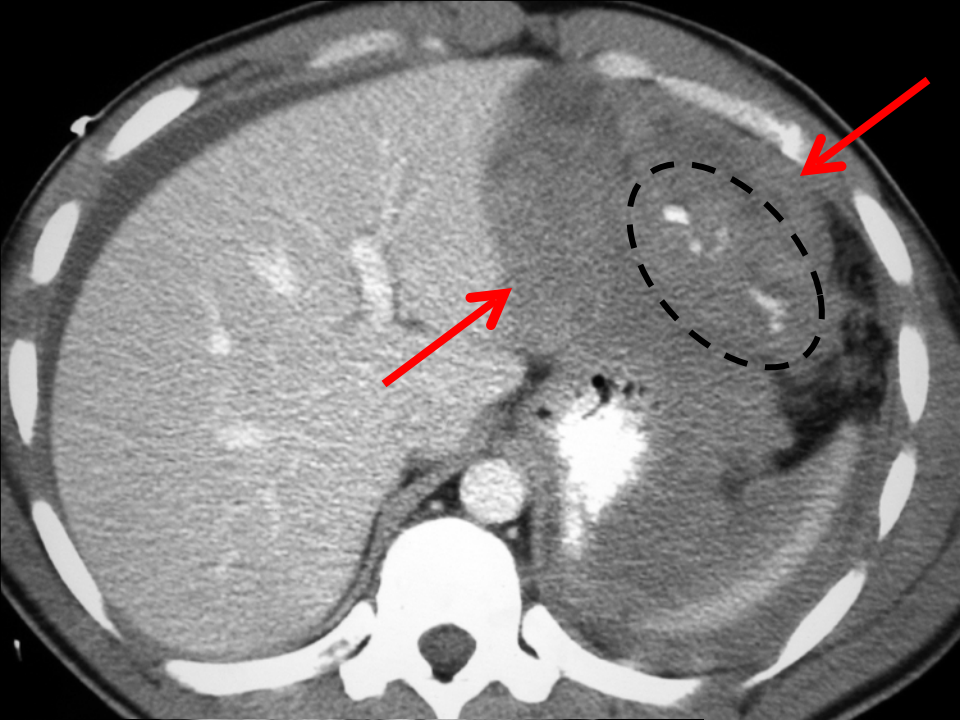


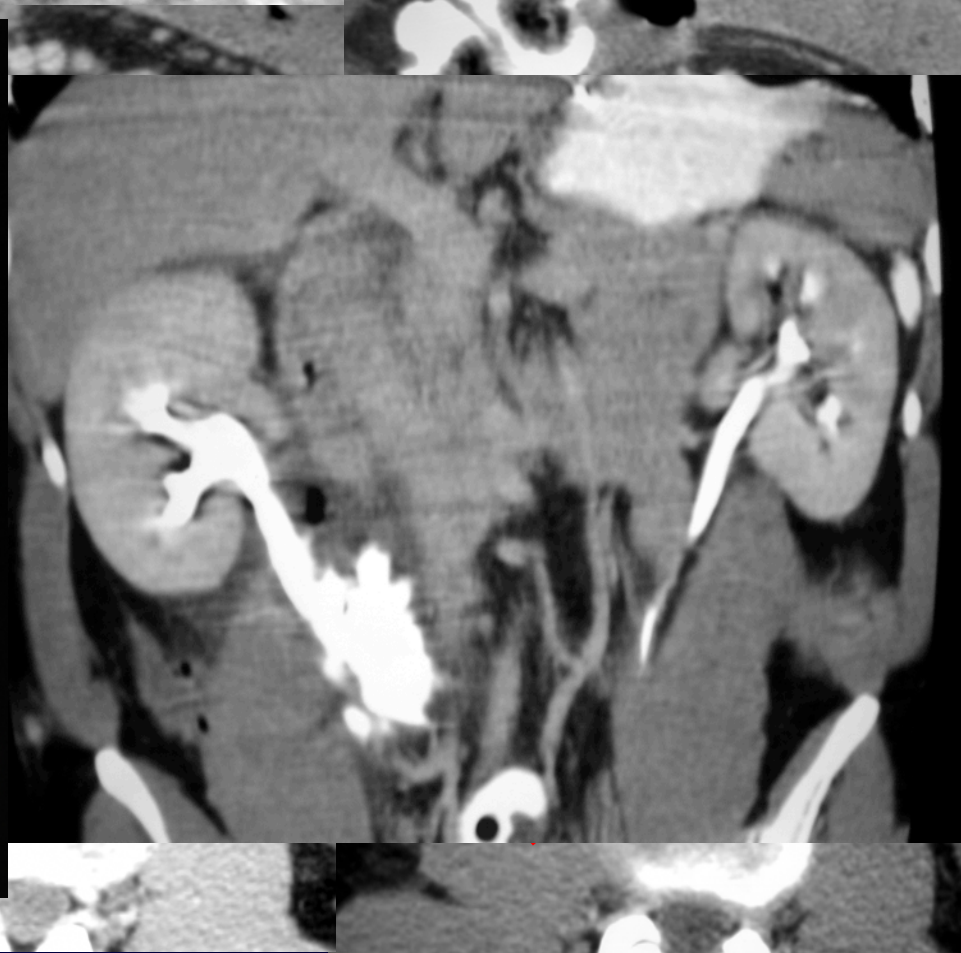
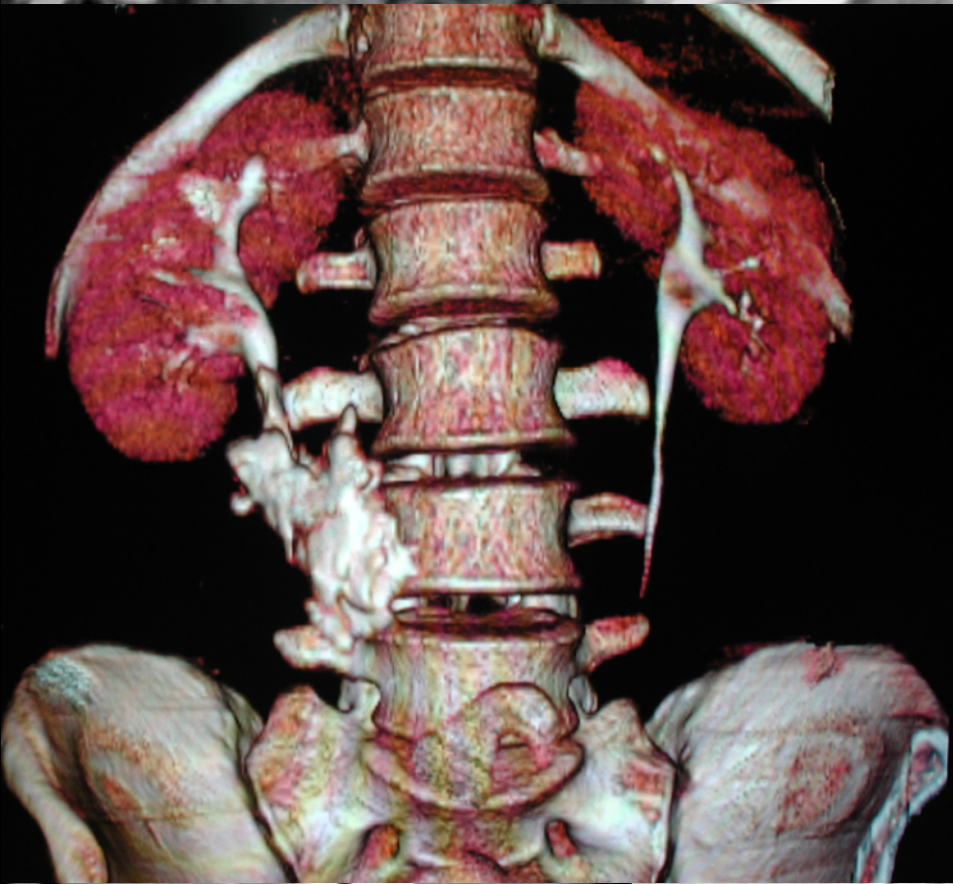
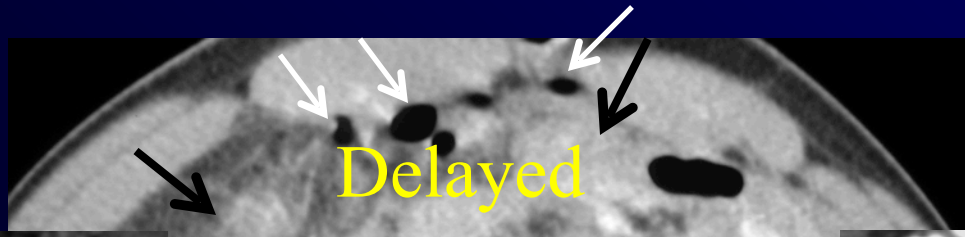












TRIPLE CONTRAST SPIRAL CT IN PENETRATING TORSO TRAUMA

BOWEL INJURY

- Oral or rectal contrast extravasation
- Extravasation of intestinal content
- Bowel wall thickening

TRIPLE CONTRAST SPIRAL CT IN PENETRATING TORSO TRAUMA

BOWEL INJURY

- Defect or discontinuity of bowel wall
- WT extending up to bowel

BOWEL INJURY

Blunt

Penetrating

	SEN	SPE	SEN	SEP
FA	++	+++++	NA	NA
FF	+++++	++	NA	NA
GI-CE	+	+++++	++	+++++
BWT	+++	++	++++	++++

TRIPLE CONTRAST SPIRAL CT IN PENETRATING TORSO TRAUMA

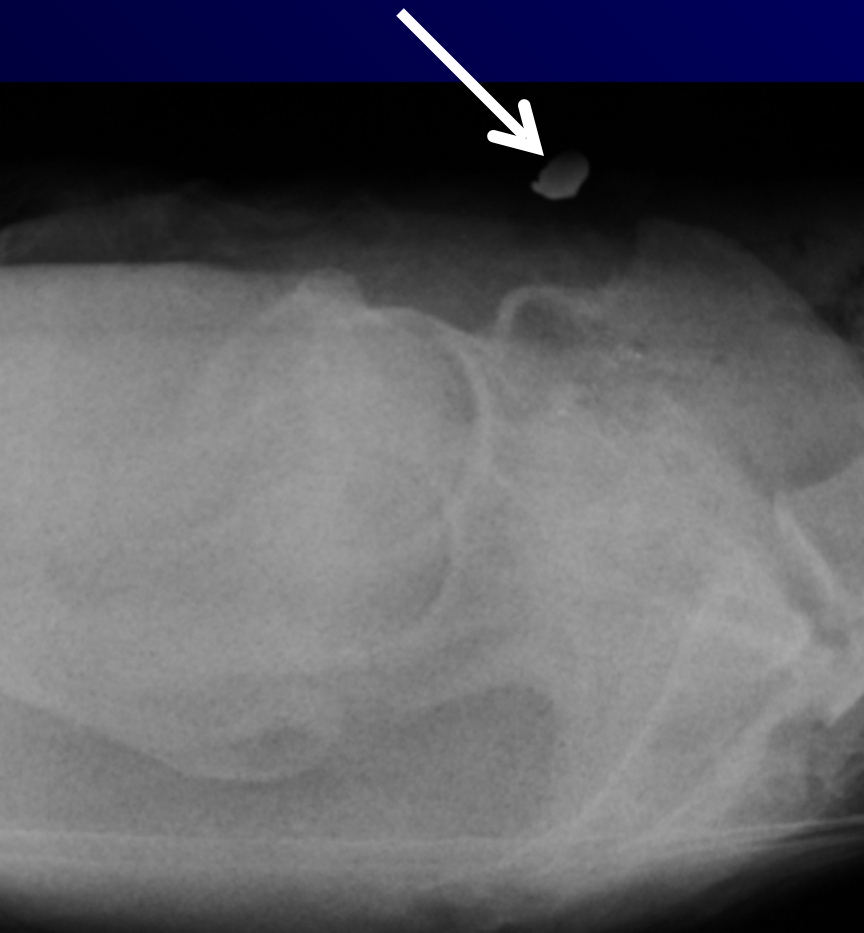
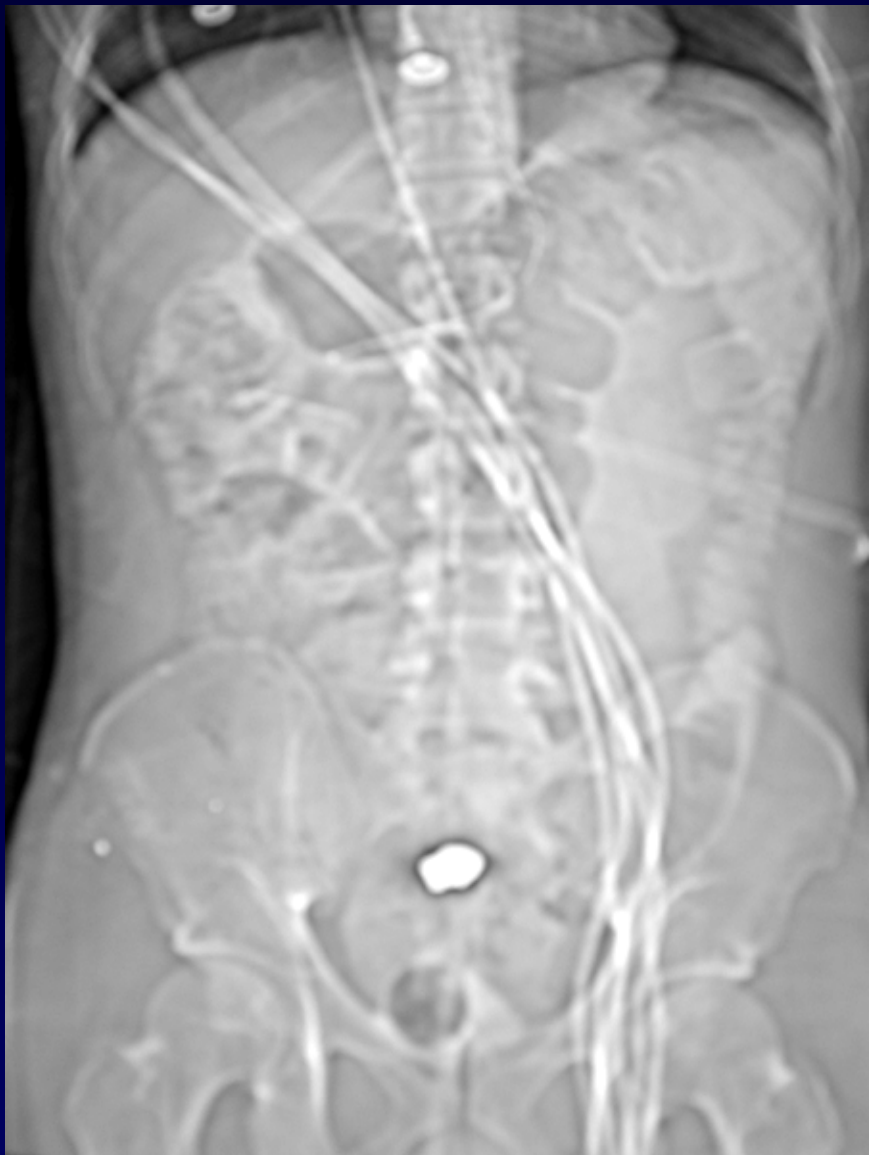MESENTERIC INJURY

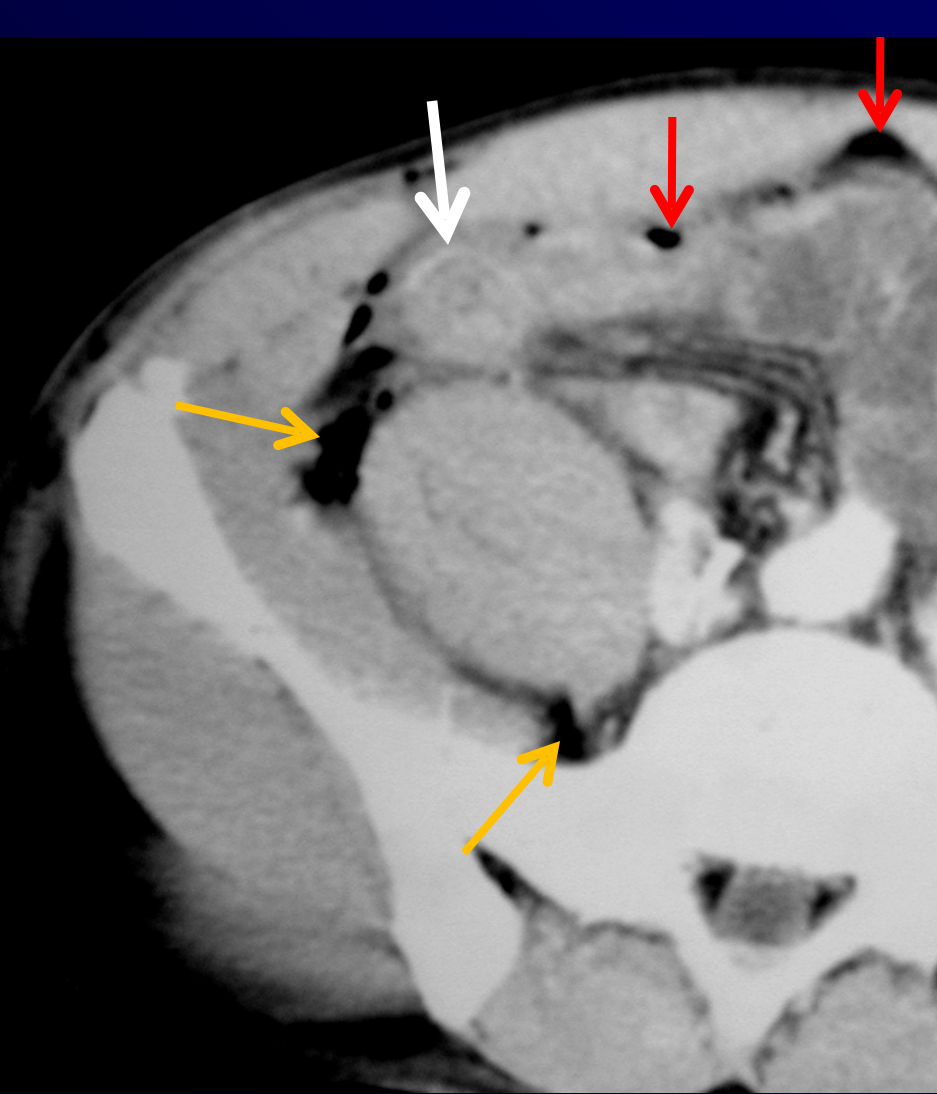
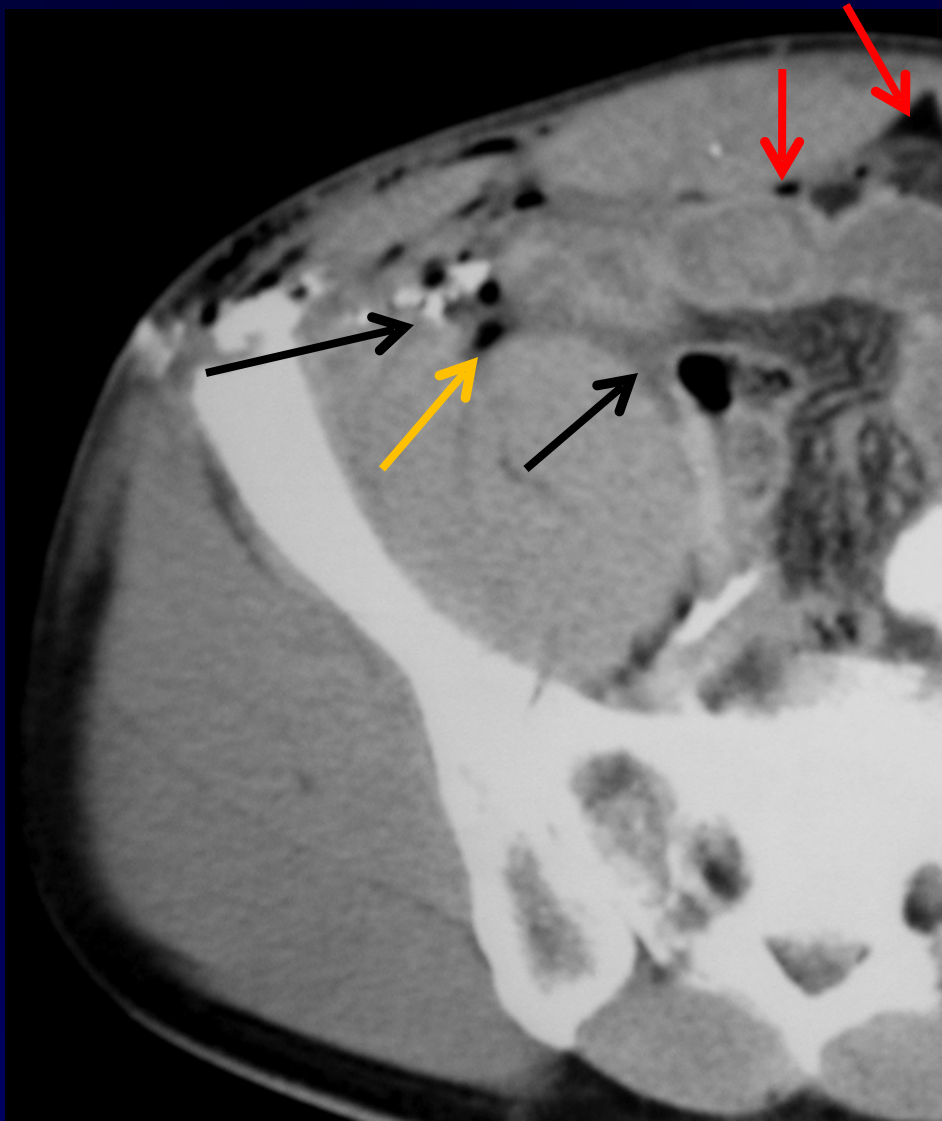
- Active bleeding - mesentery
- Focal hematoma
- Stranding or infiltration

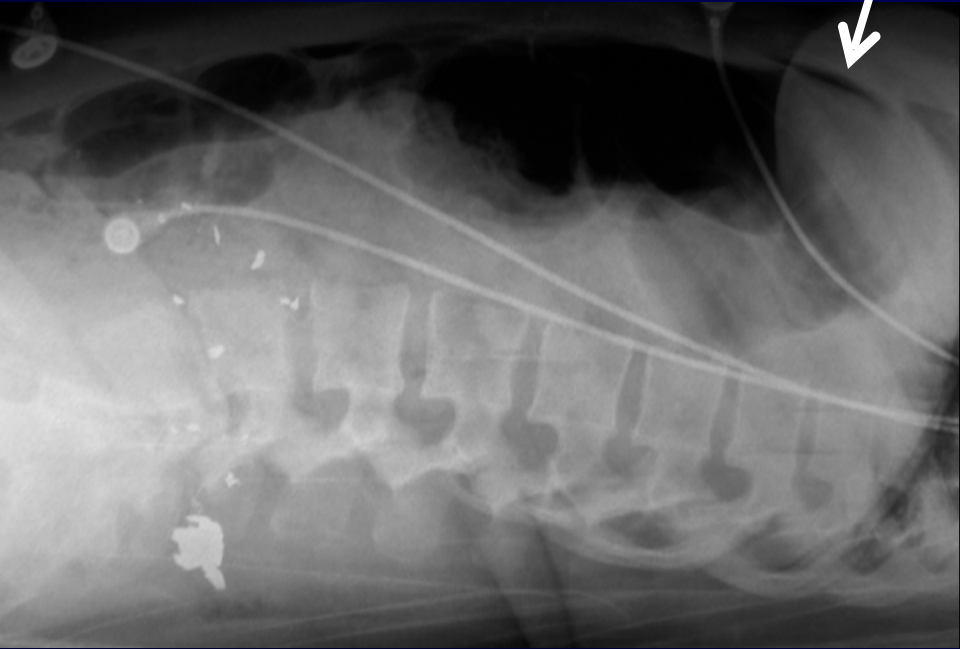
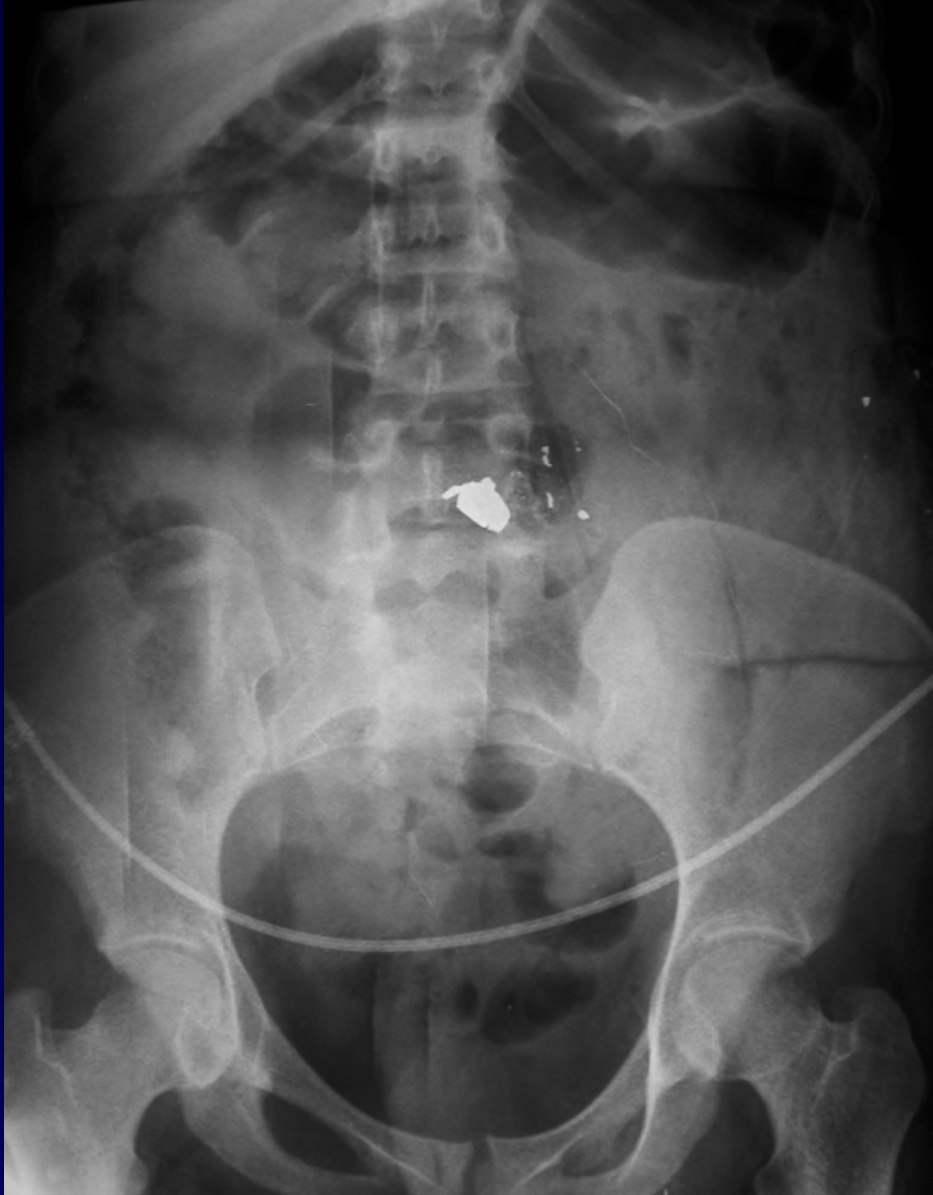TRIPLE CONTRAST SPIRAL CT IN PENETRATING TORSO TRAUMA

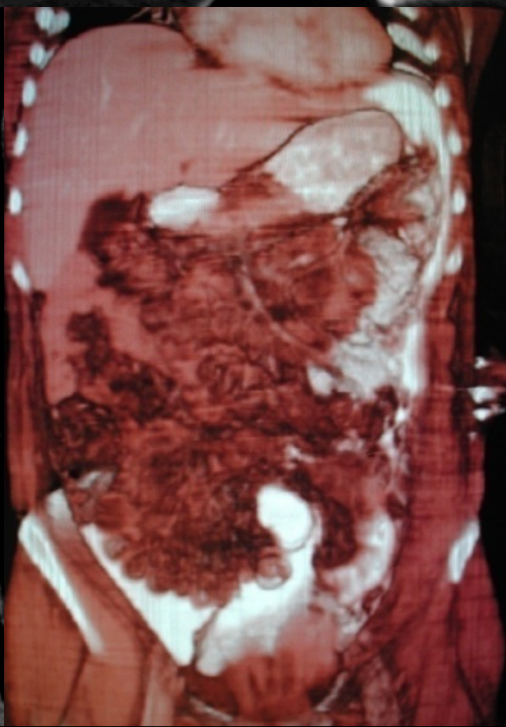
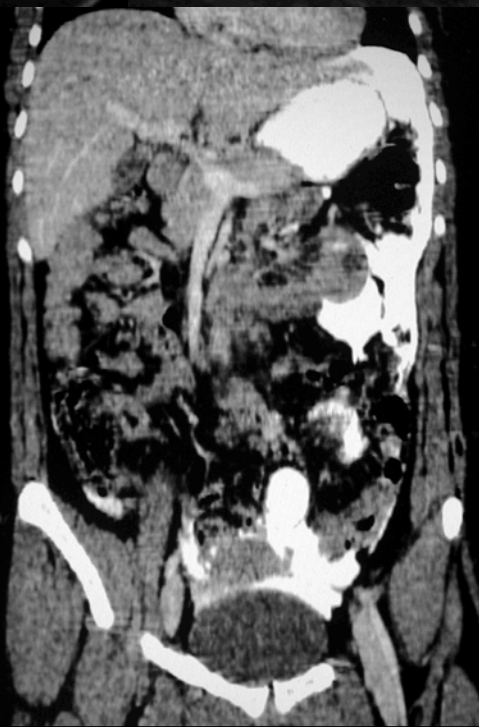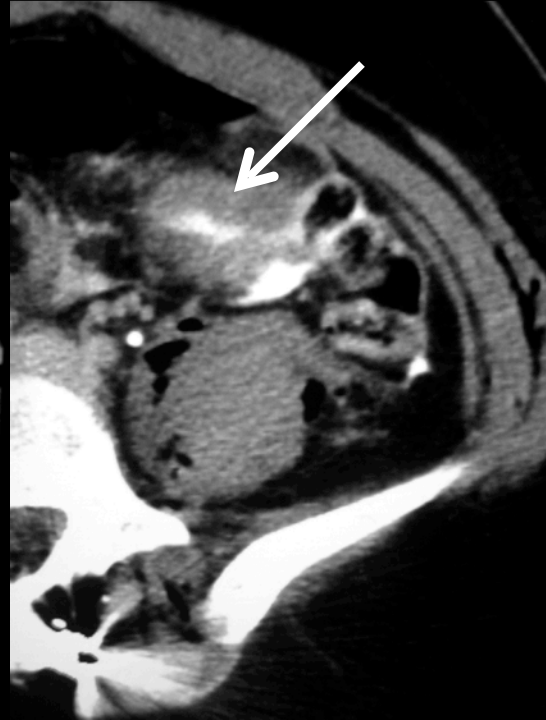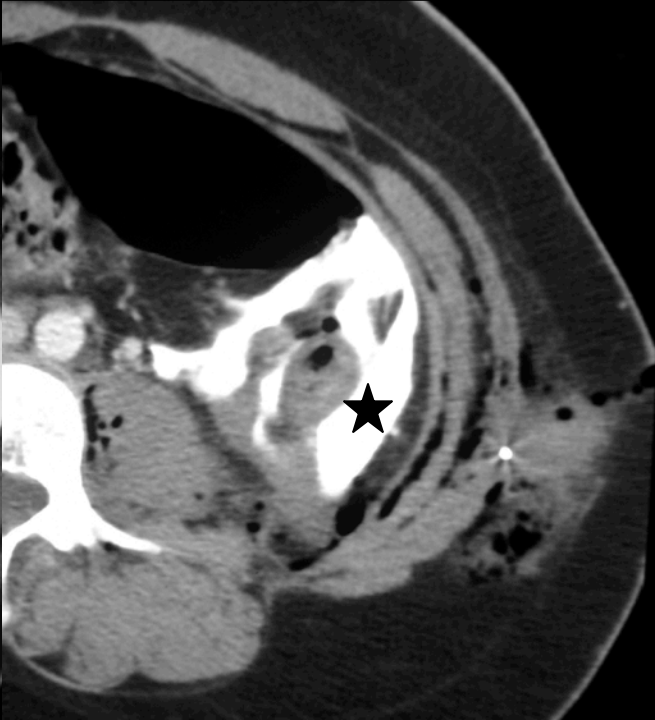
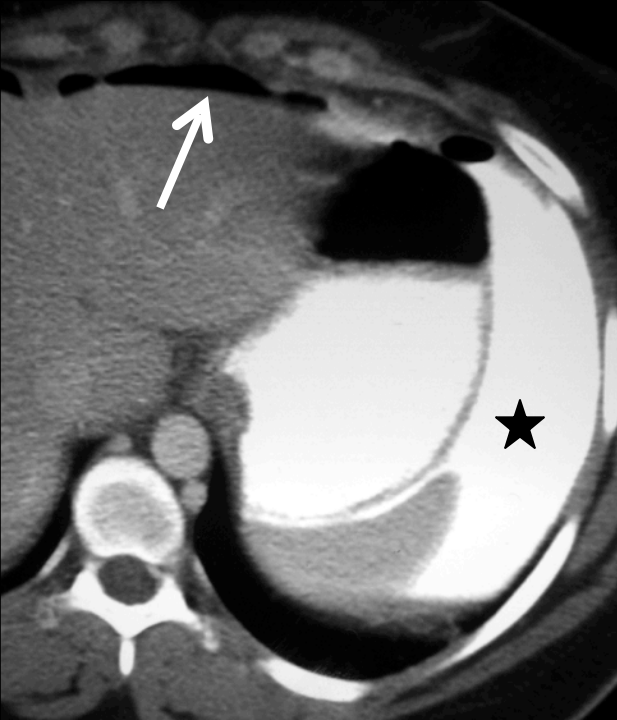
RESULTS BOWEL INJURY 26/200

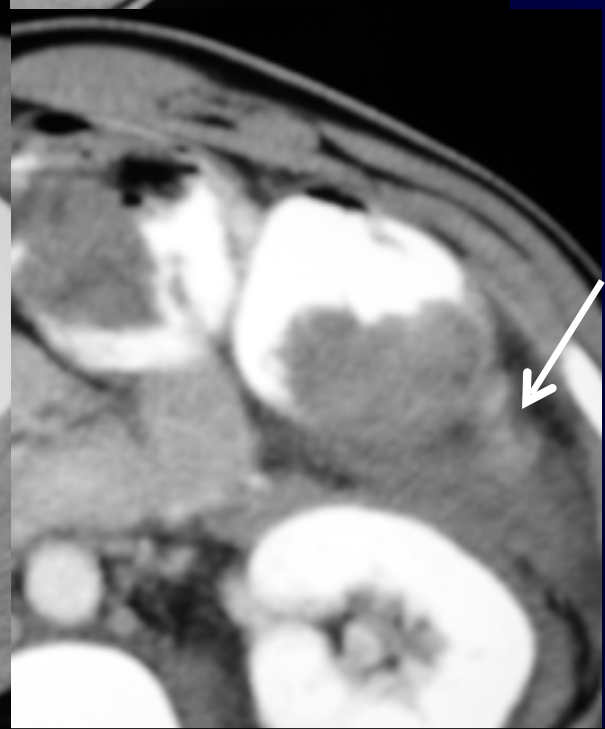
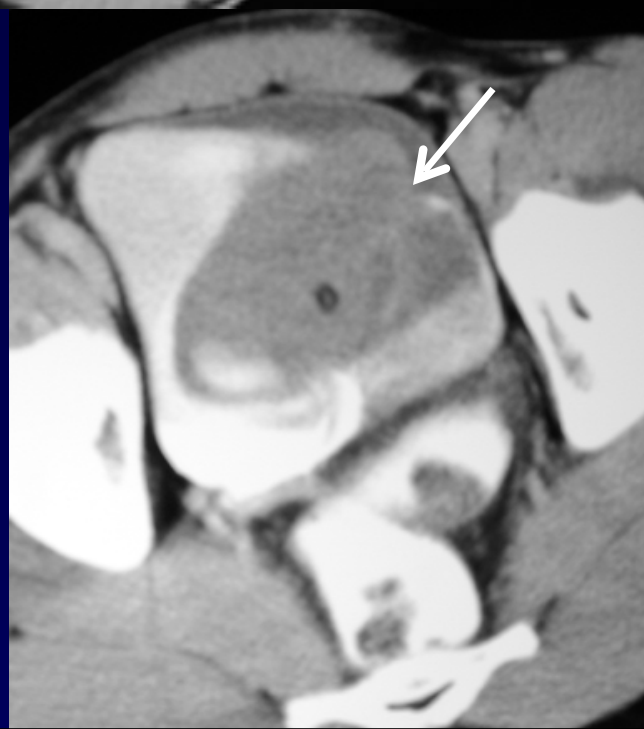
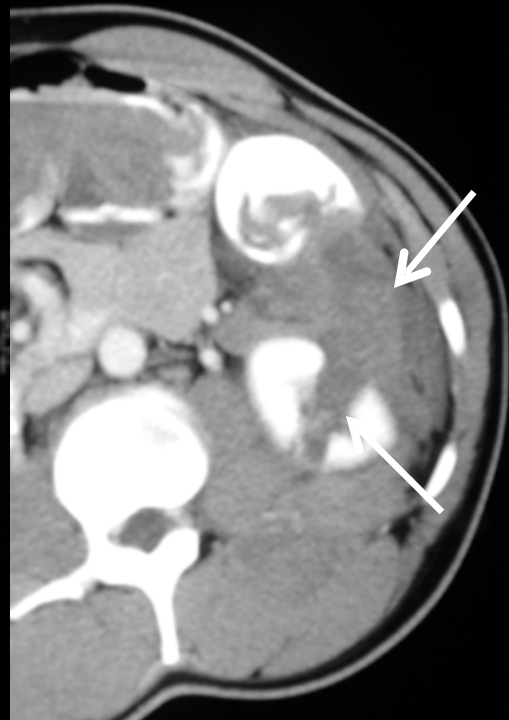
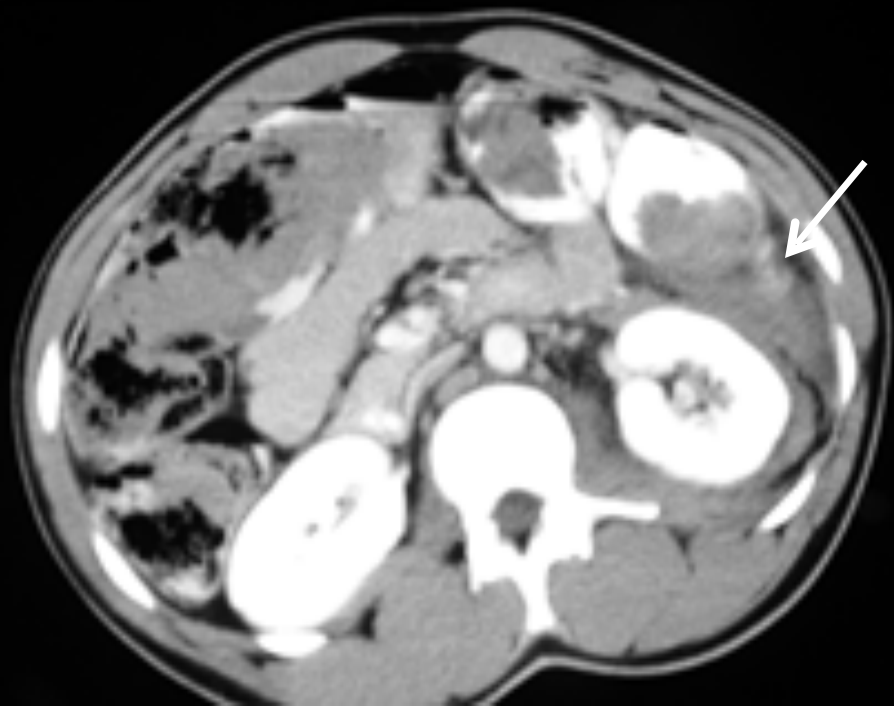
• WOUND TRACT	20/26	70 %
• BOWEL WALL THICKENING	11/26	42 %
• CONTRAST LEAK ORAL/RECTAL	5/26	19 %

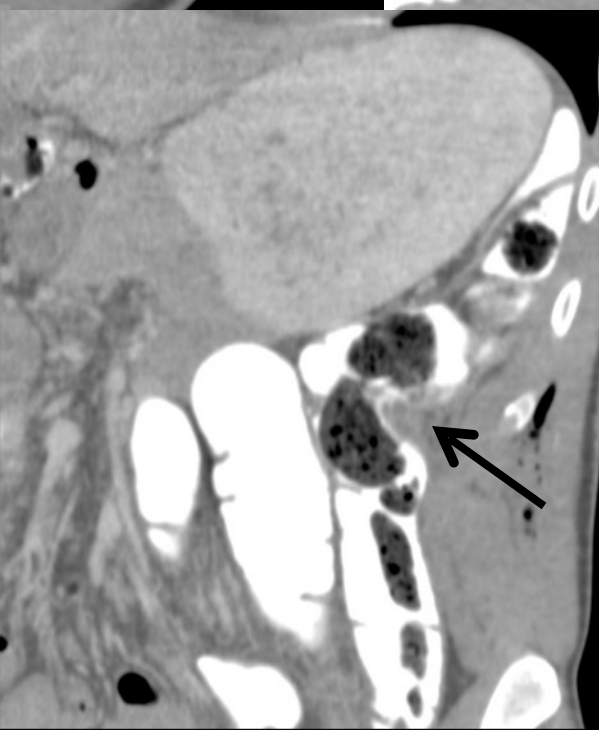
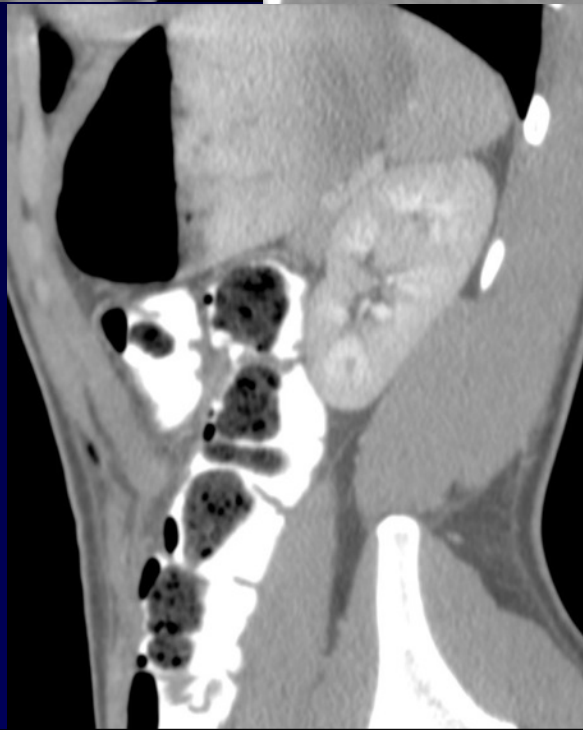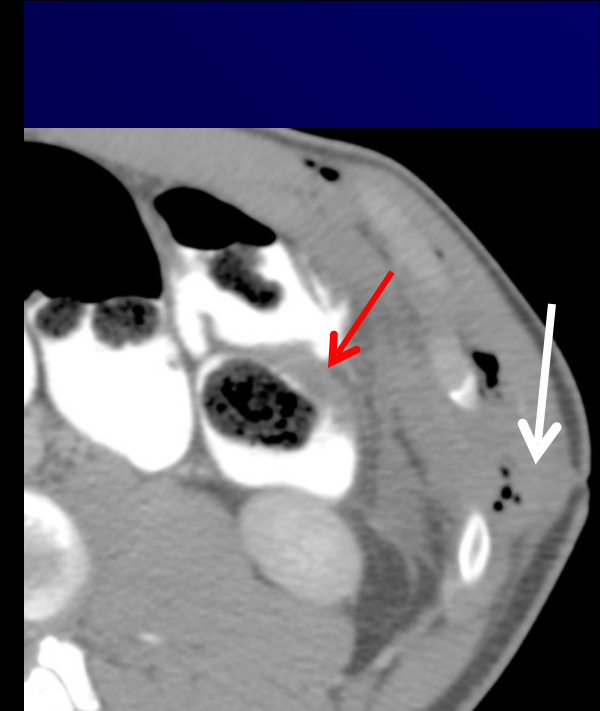
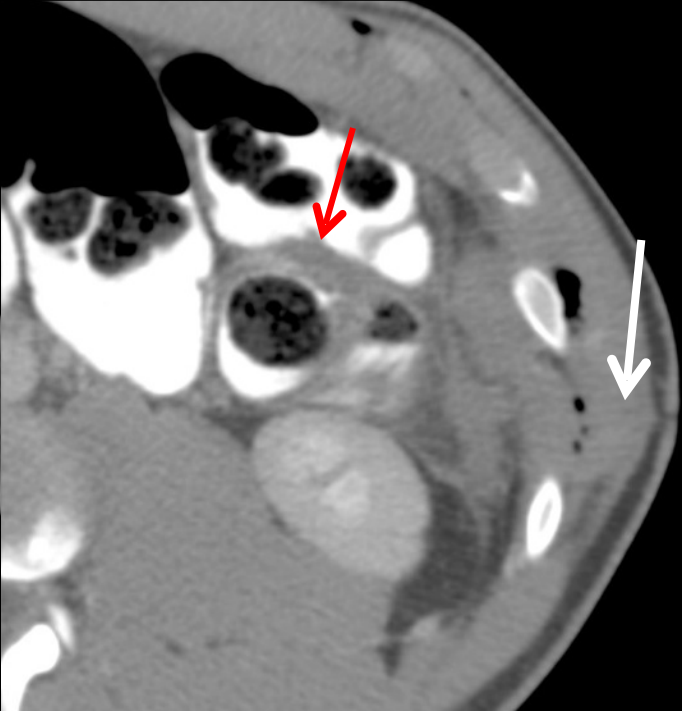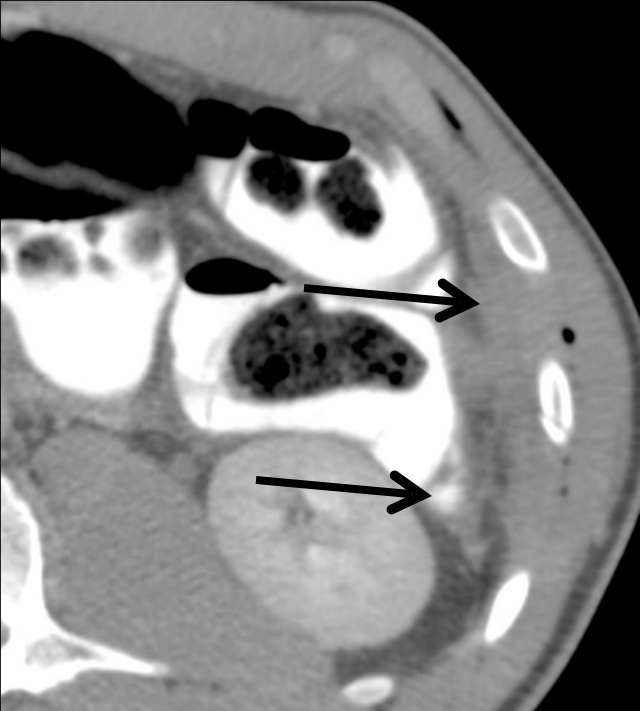


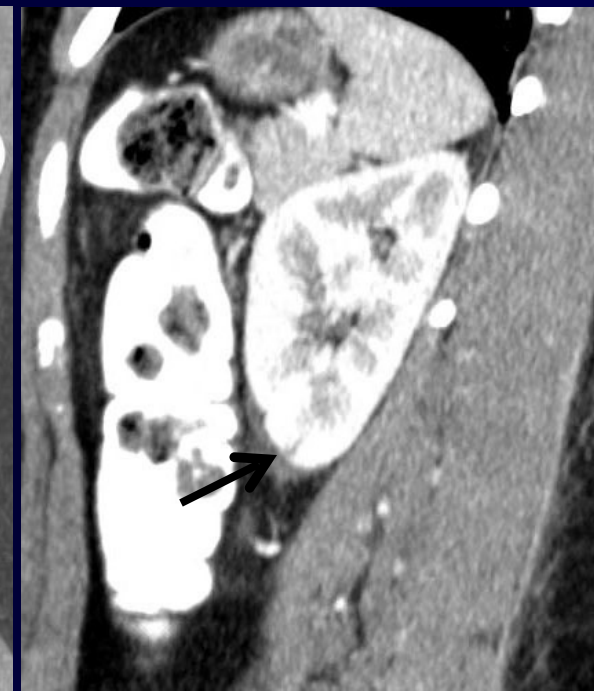
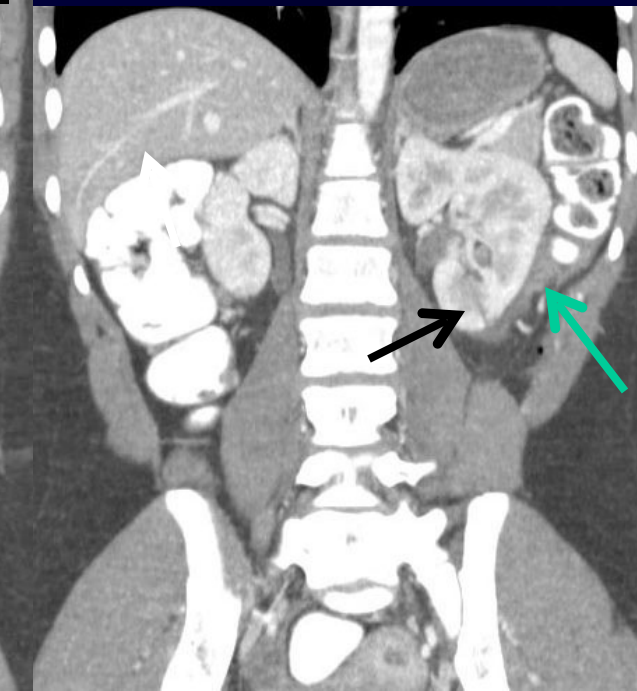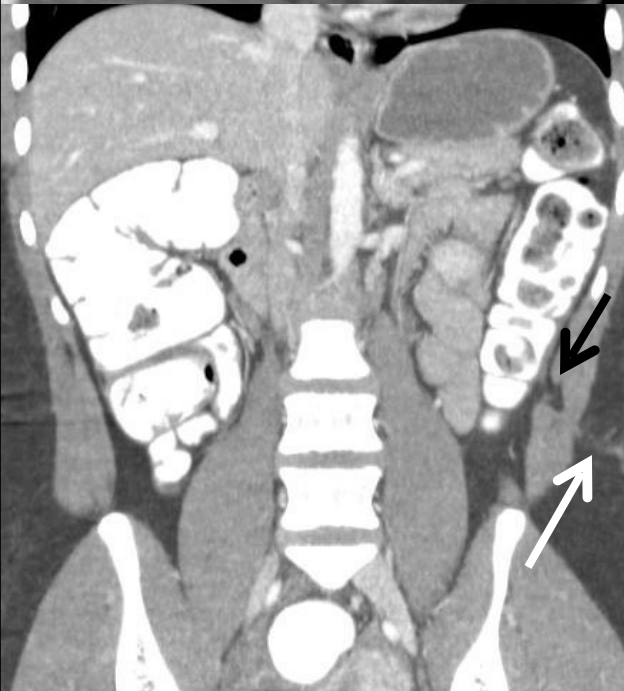


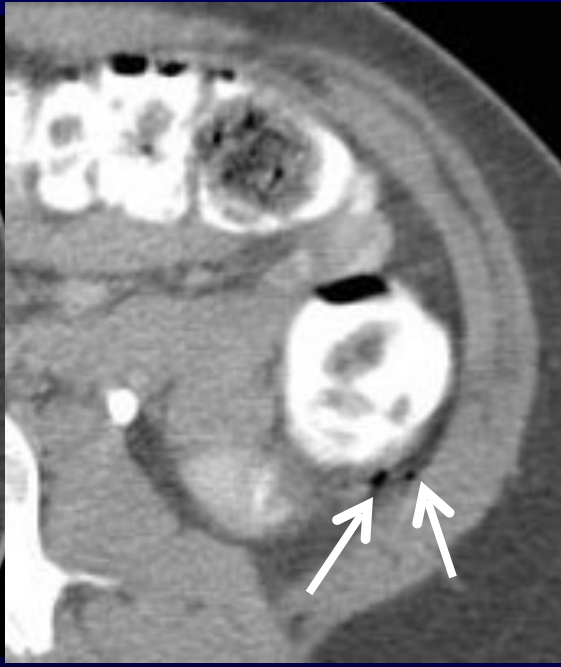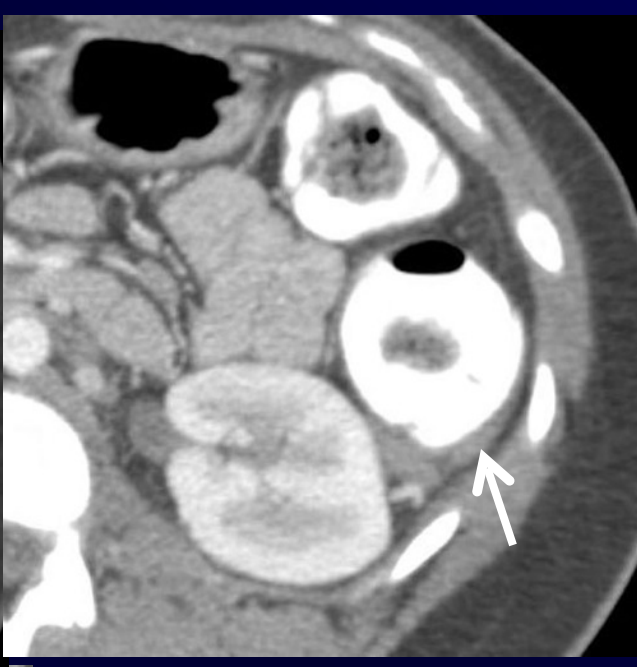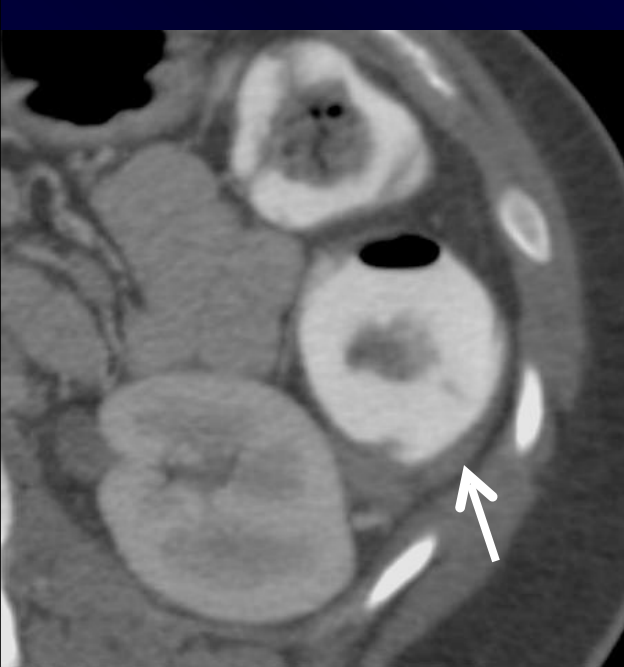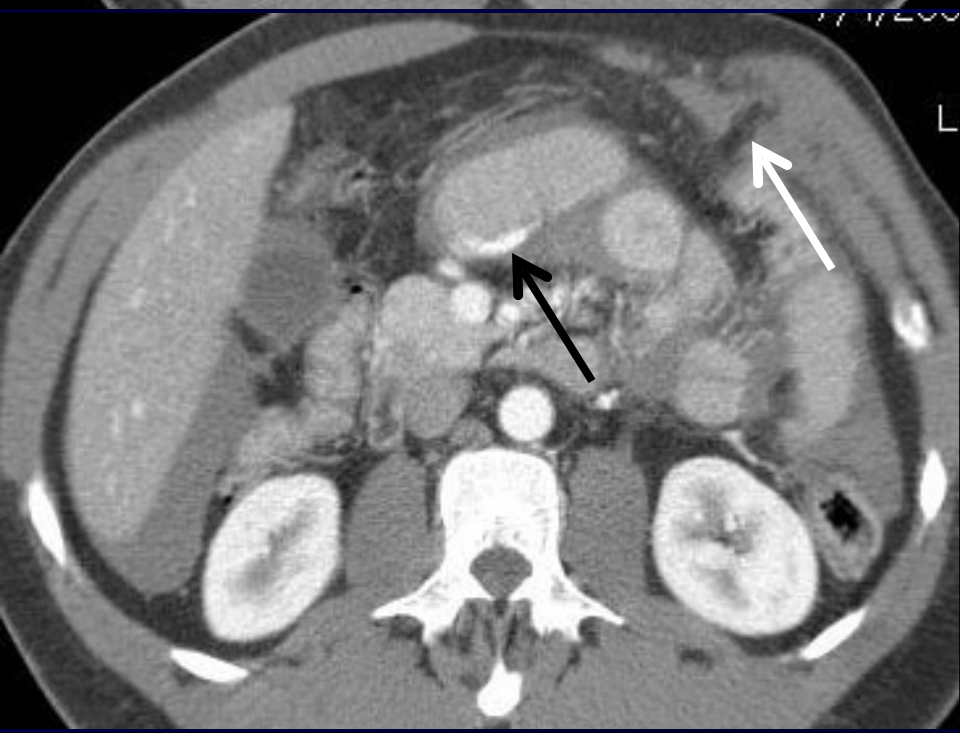
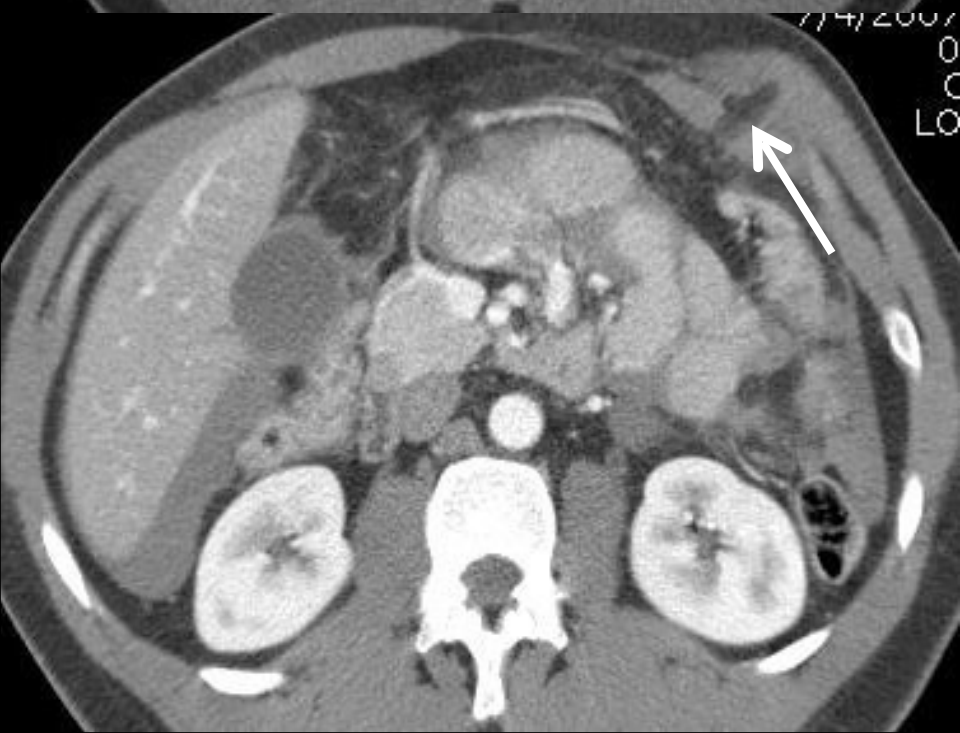
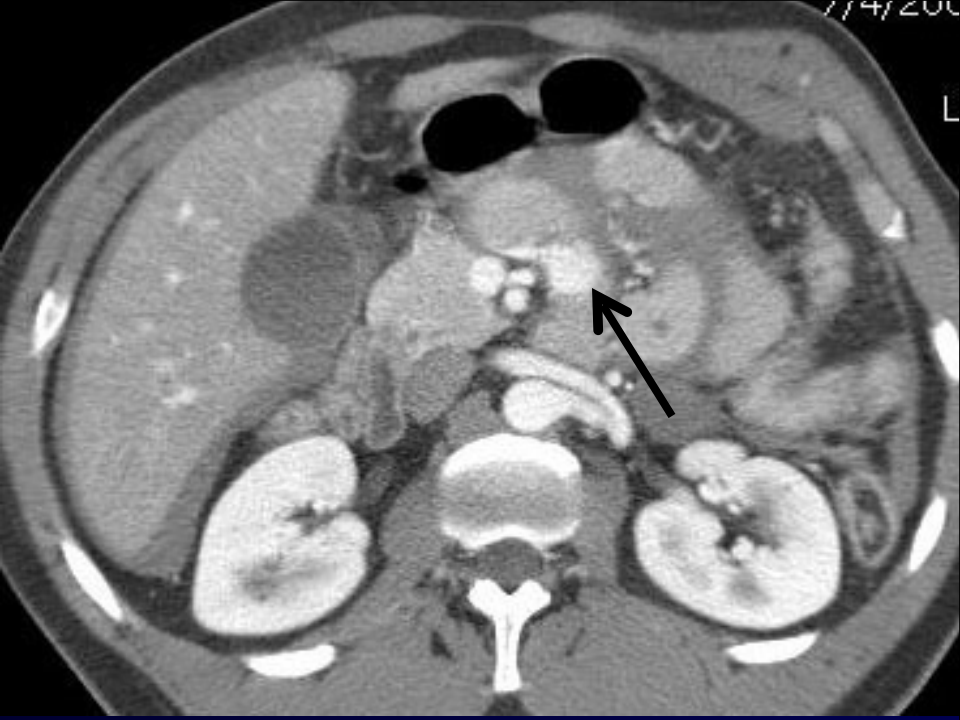
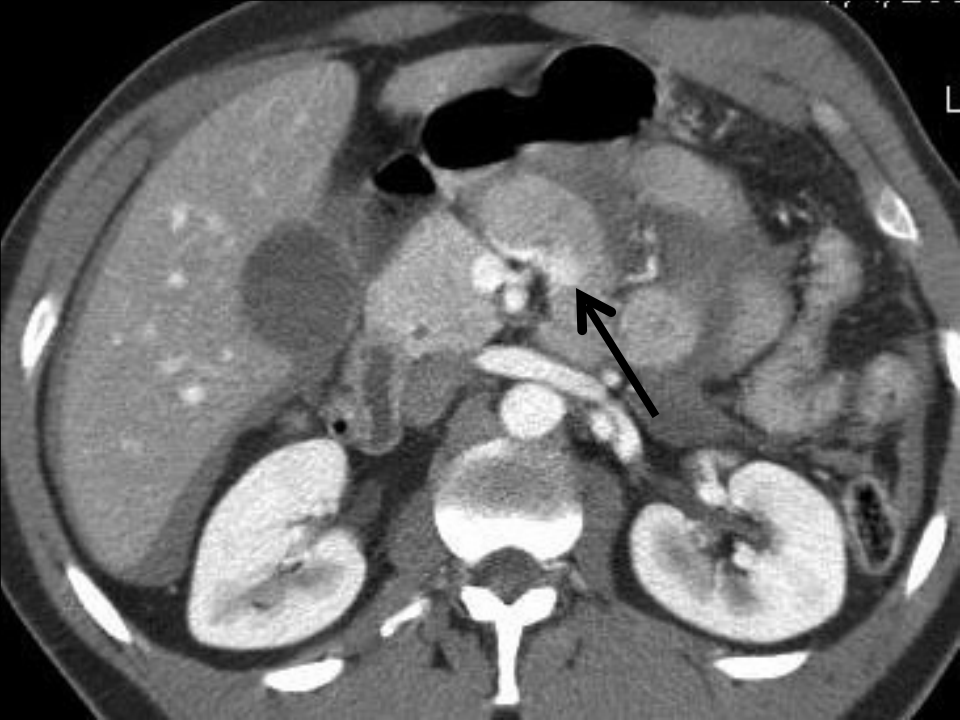


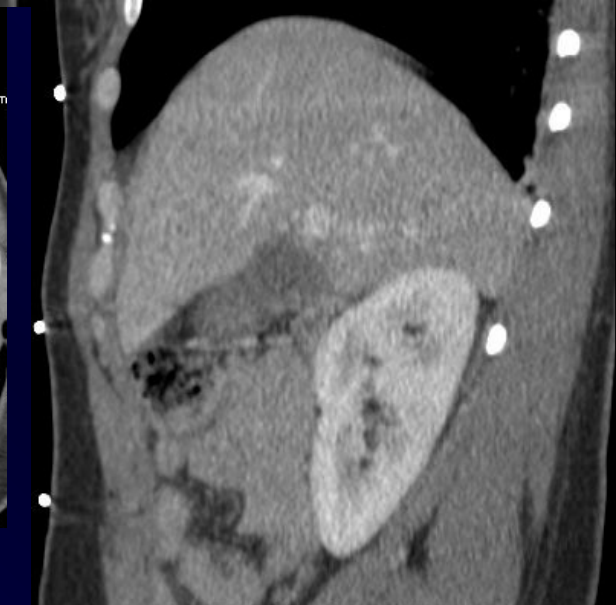
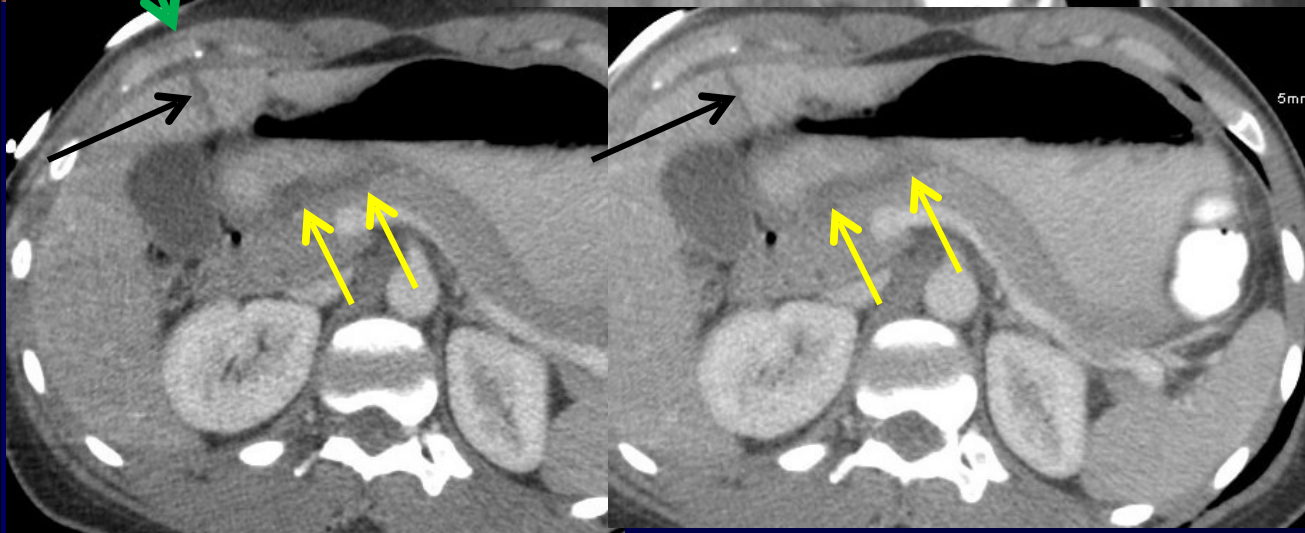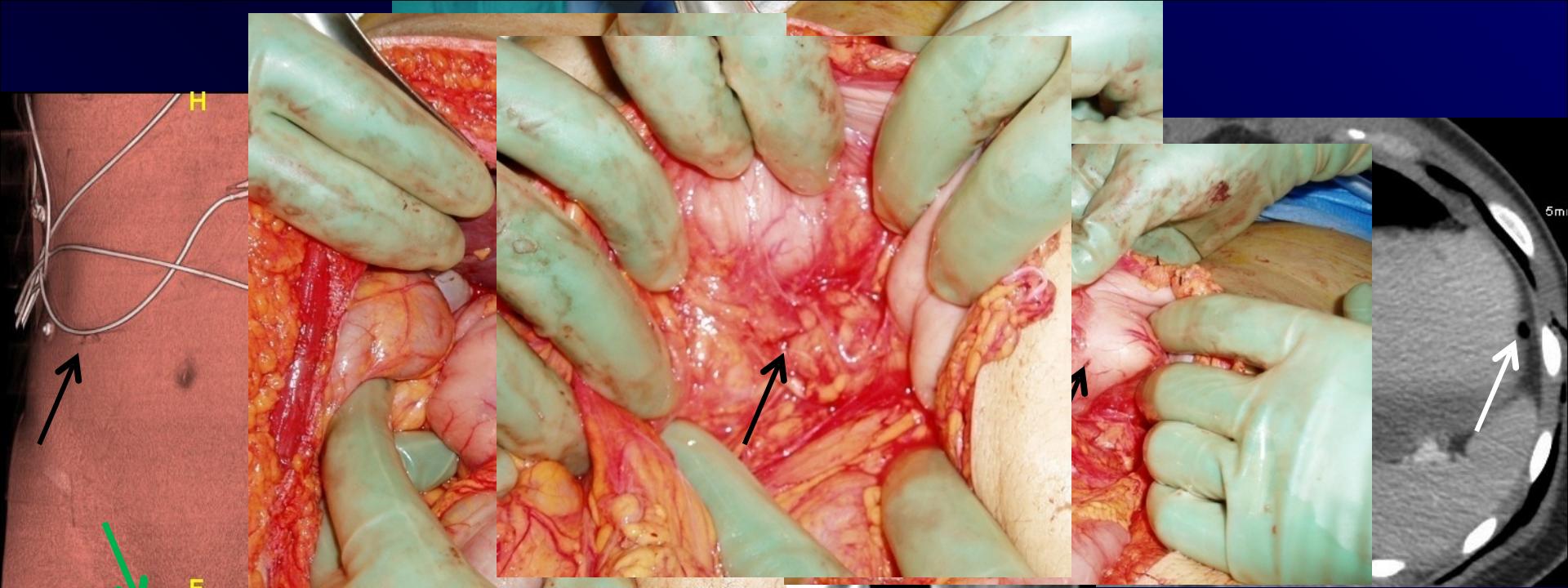


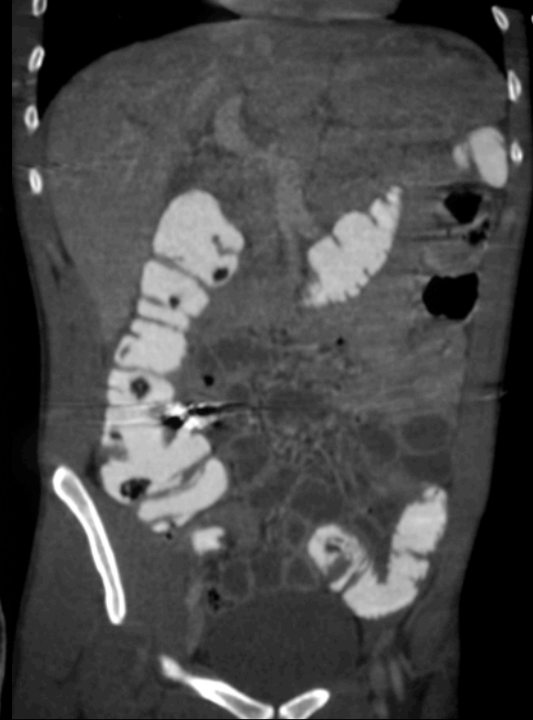
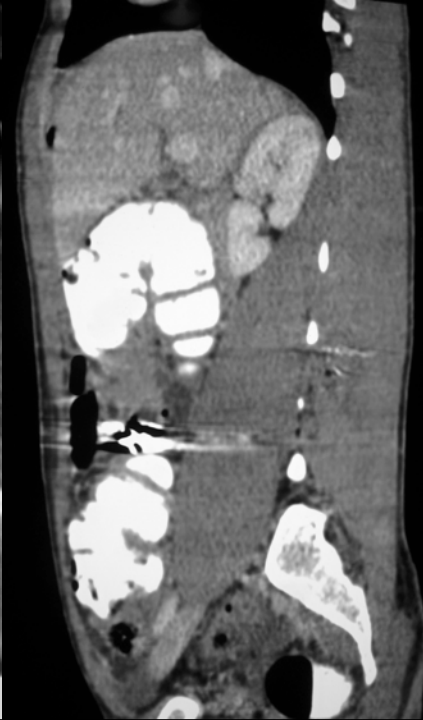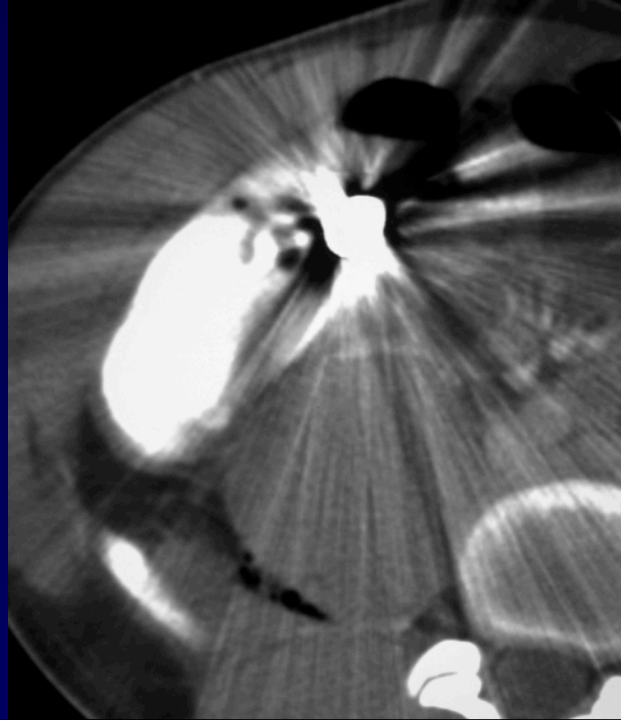
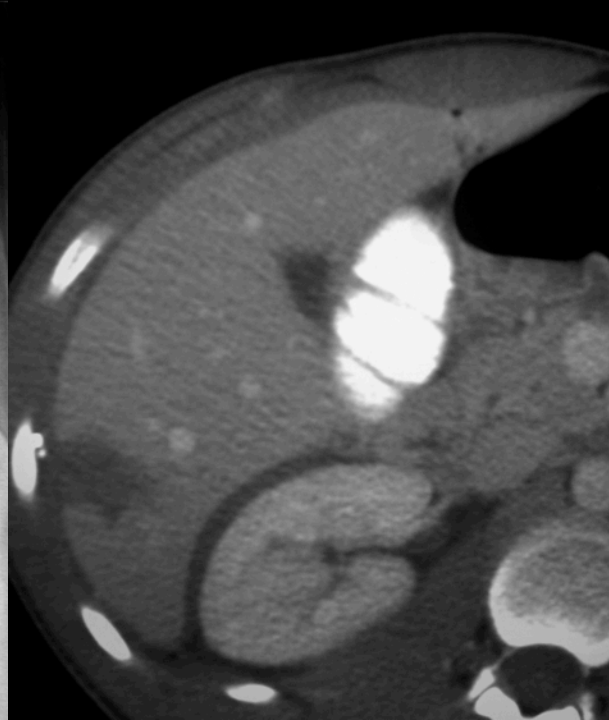
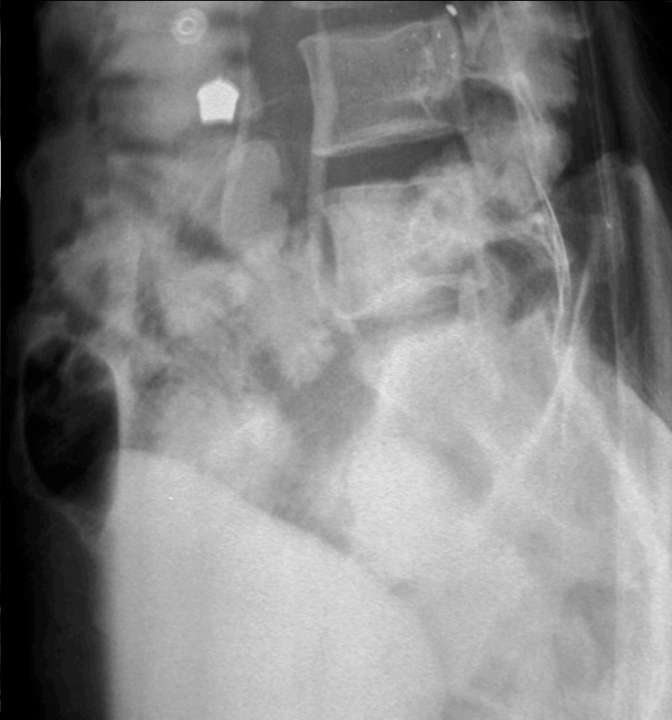


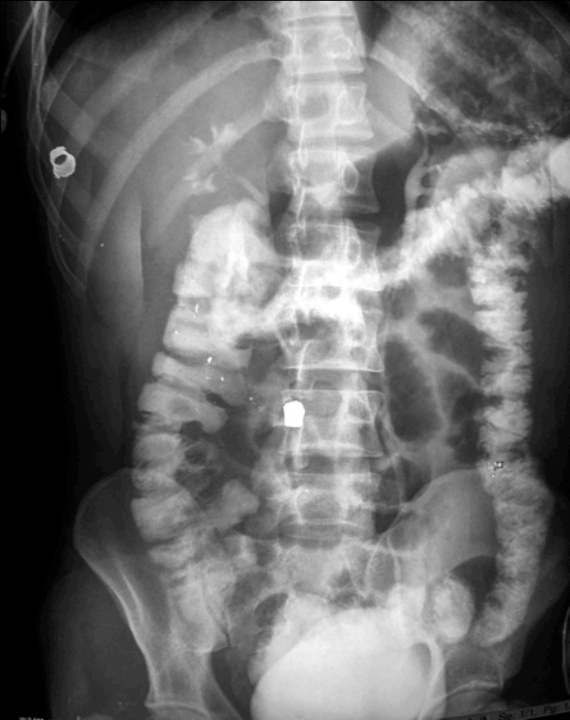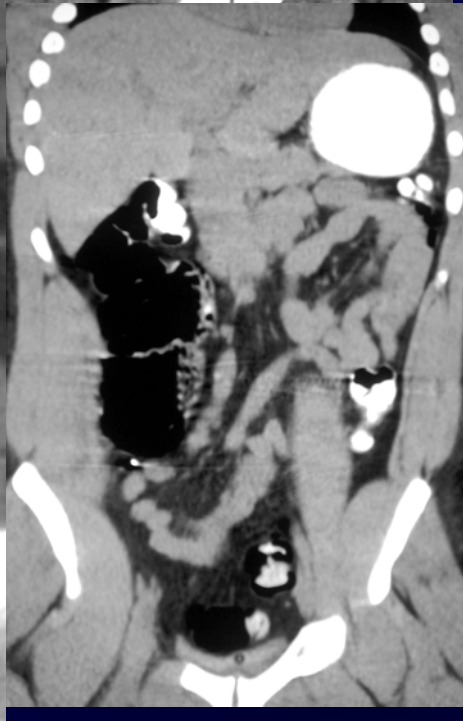
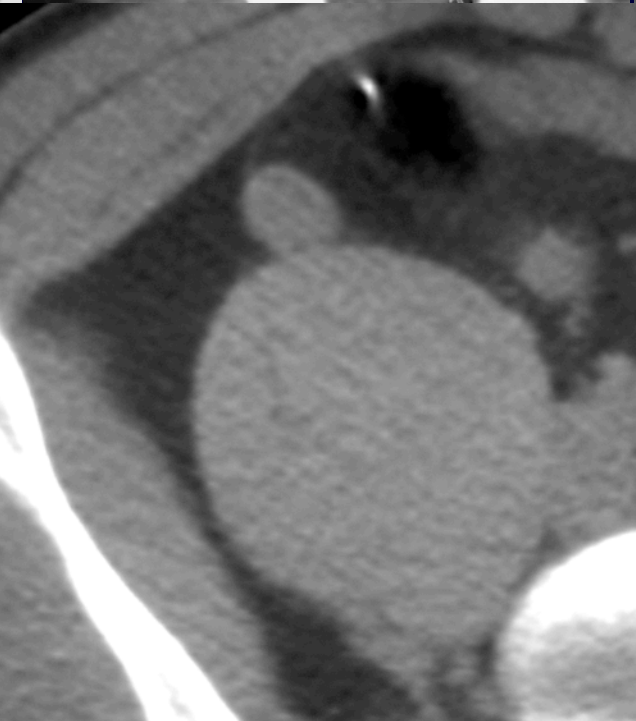
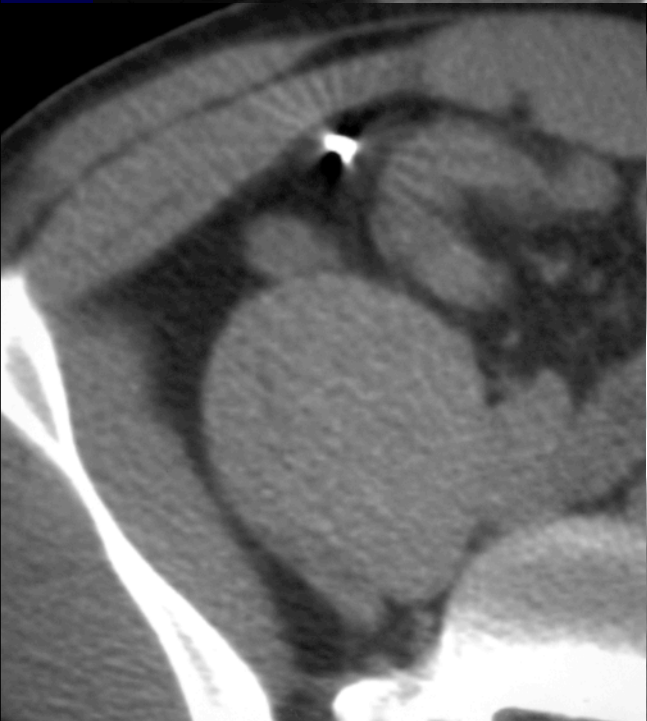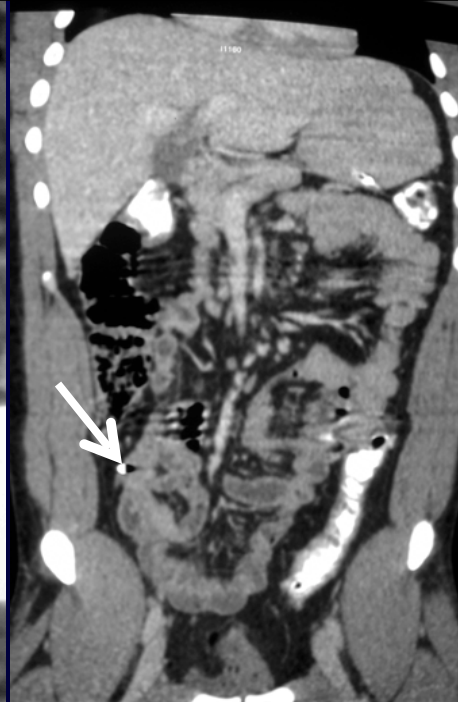
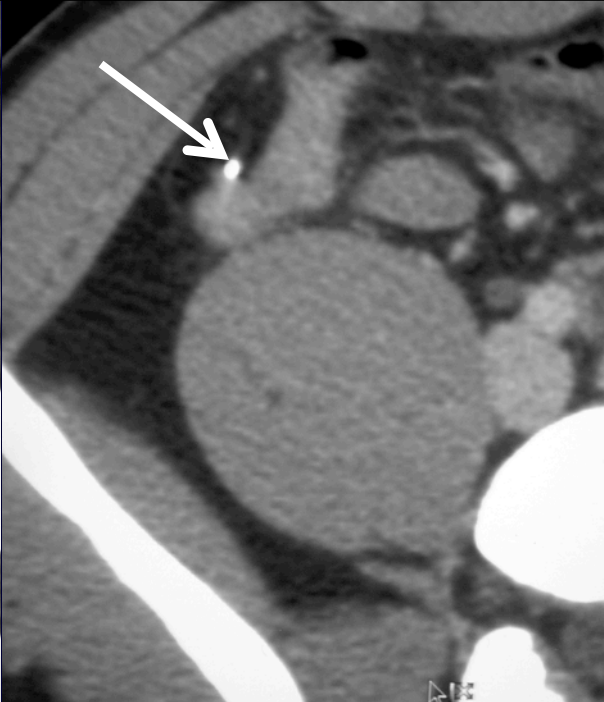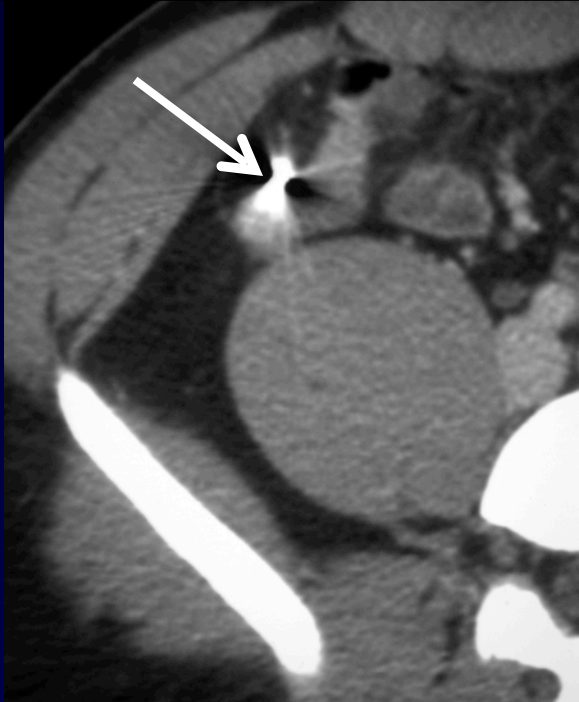


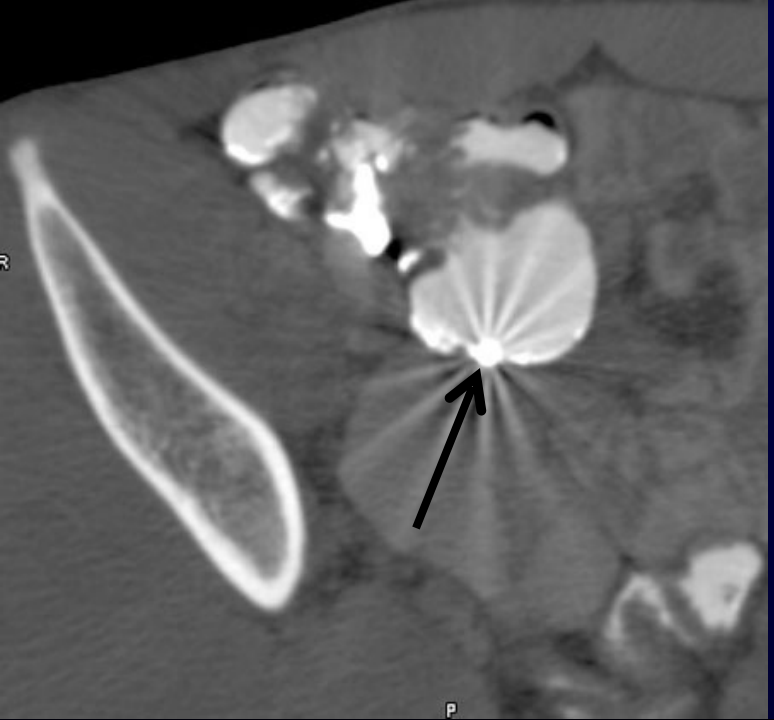











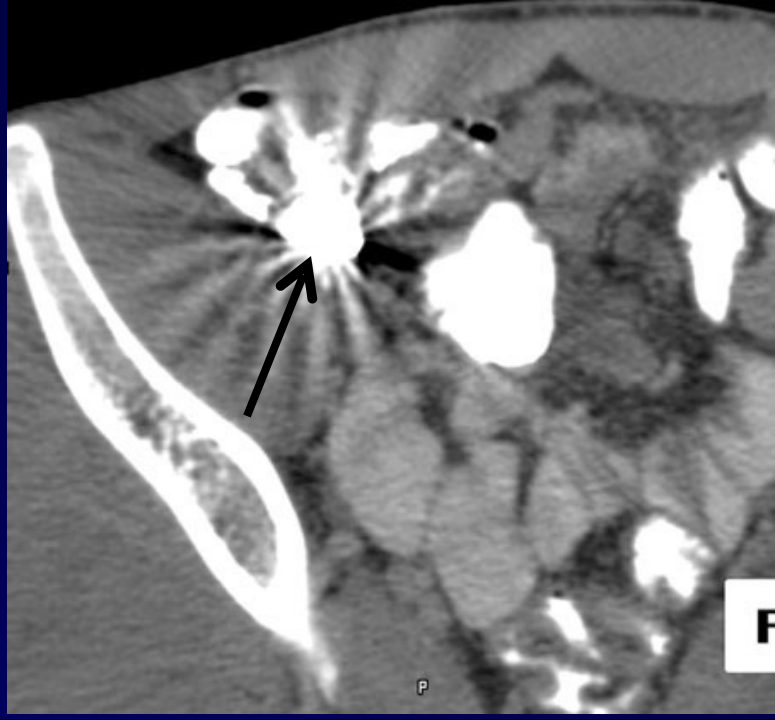
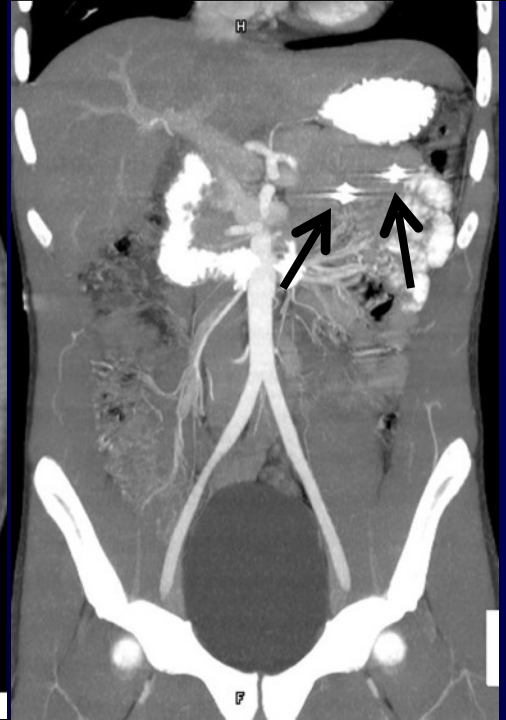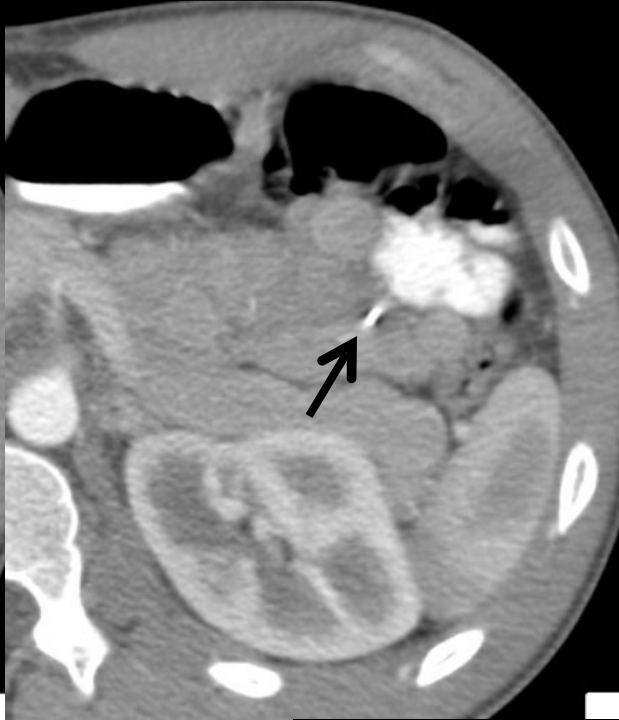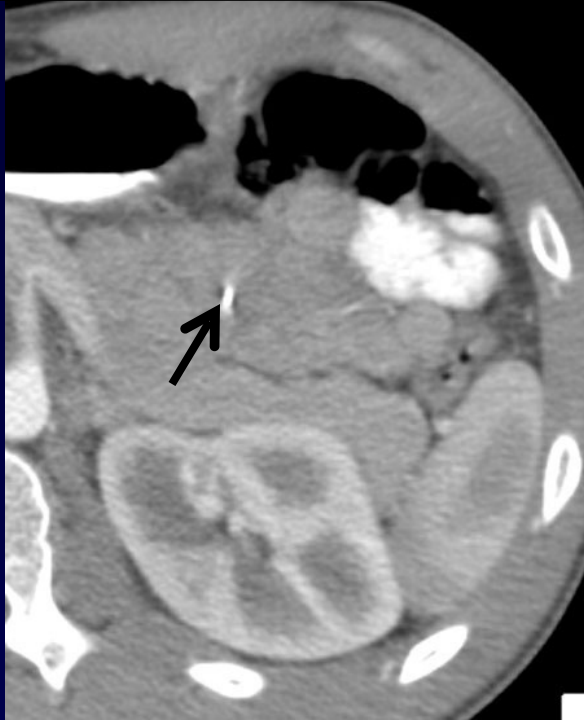TRAUMA “WHOLE BODY” MDCT PROTOCOLS

<i>MDCT</i>	<i>Contrast Volume</i>	<i>I₂ mg/mL</i>	<i>Rate</i>	<i>Delay</i>	<i>Detector width</i>	<i>Pitch</i>	<i>Rotation time</i>	<i>Bolus * Pro</i>
<i>16- slice</i>	150 mL	300 mg/mL N.Saline	90ml – 6mL/sec 60ml – 4mL/sec 50ml – 5mL/sec	Bolus pro 90 HU	0.75 mm	0.938	0.5 sec	Ascending Aorta
<i>40 & 64-slice < 50 yrs</i>	100 mL	350 mg/mL N.Saline	50ml – 6mL/sec 50ml – 4mL/sec 50ml - 5mL/sec	18 sec	0.625 mm	0.976	0.5 sec	Nil
<i>40 & 64 -slice > 50 yrs</i>	100 mL	350 mg/mL N.Saline	50ml – 6mL/sec 50ml – 4mL/sec 50ml - 5mL/sec	Bolus pro 90 HU	0.625 mm	0.976	0.5 sec	Ascending Aorta

